

CASE REPORT

Open Access



Intracranial meningioma: an unusual silent killer—about two cases report and a literature review

Mohamed Amine Mesrati^{1*}, Oumeima Brahim¹, Marwa Boussaid¹, Rakia Soiniya¹, Yosra Mahjoub¹, Nouha Ben Abdeljelil¹, Atef Ben Ncir¹, Abdelfattah Zakhama¹ and Abir Aissaoui¹

Abstract

Background Meningiomas are common benign intracranial tumors, accounting for 1/3 of all primary intracranial neoplasms, and hence, are not considered the chief cause of death when encountered incidentally during autopsy. These tumors are usually slow-growing, and the clinical course may be asymptomatic to the point of acute complications. Sudden unexpected deaths due to meningiomas are exceptional and rarely reported in the literature.

In the present report, we describe two autopsy cases of sudden unexpected death due to meningiomas and we discuss the mechanism of death.

Case presentation Two apparently healthy men were discovered dead in their home. A judicial autopsy was ordered. At dissection, a pedunculated firm mass, attached to the dura was found in both cases. Tumors were located in the anterior and middle fossa. The remaining organs were congestive without any abnormality. A microscopic examination confirmed the diagnosis of meningiomas. Postmortem toxicology analysis was negative. Forensic pathologists concluded to sudden unexpected death due to intracranial meningioma.

Conclusions These cases illustrate the possibility of meningioma remaining silent till acute complication and fatal outcome. Therefore, clinicians must bear in mind the possibility, albeit extremely rare, of sudden unexpected death in cases of undiagnosed intracranial meningiomas, as documented in the present report. Thus, we emphasize the value of promptly and thoroughly investigating even seemingly minor neurological symptoms, such as headaches or acute epileptic seizures, in adults. We also stress the importance of the early detection and appropriate management of brain tumors in fatal outcome prevention, and we highlight the role of the post-mortem examination to detect such a fatal complication.

Keywords Brain neoplasms, Meningioma, Sudden unexpected death, Autopsy, Cause of death

Background

Sudden deaths caused by diseases of the central nervous system are generally the consequence of cerebrovascular accidents, infections, neoplasms, degenerative diseases, and seizures (Gitto et al. 2018; Wiemels et al. 2010). Sudden unexpected death due to a previously unrecognized primary intracranial tumor is extremely rare accounting between 0.04 and 0.24% (Zouaoui et al. 2018; Nakamura et al. 2003), and malignant ones are the cause of the most sudden death cases (Vougiouklakis et al. 2006;

*Correspondence:

Mohamed Amine Mesrati
mohamed.amine.mesrati.1@gmail.com; mesrati.amin@gmail.com

¹ Faculty of Medicine of Monastir, University of Monastir, Monastir 5100, Tunisia

Yp et al. 2016). Among deaths secondary to intracranial neoplasms, sudden deaths from meningioma have been rarely reported in the literature (Gitto et al. 2018; Kim et al. 2013; Vougiouklakis et al. 2006; Wiemels et al. 2010; Yp et al. 2016).

Meningioma, widely known as a meningeal tumor, is characteristically a tumor that grows slowly originating in the meninges, the membranous layers that cover the brain and spinal cord (Wiemels et al. 2010). It is defined by the World Health Organization as a meningotheelial cell neoplasm, typically attached to the inner dural surface (Gitto et al. 2018). The term “meningioma” was first used by Harvey Cushing in his monography “Meningiomas. Their classification, Regional Behaviour, Life History and Surgical End Results” published in 1938 (Gitto et al. 2018).

Based on statistics (Gitto et al. 2018), meningiomas are commonly described as benign tumors accounting for 13 to 26% of all primary intracranial neoplasms that most frequently affect women, with the highest occurrence in those older than 70 years (Zhang et al. 2017). Malignant meningiomas, nevertheless, are rare and more often encountered in men (Zhang et al. 2017). According to the WHO, meningiomas can be classified as follows: “grade 1”—a lowgrade neoplasm with slow growth and little tendency to recur; “grade 2”—atypical meningioma, with more aggressive local growth and high tendency to recur; and “grade 3”—anaplastic meningioma (malignant) (Voß et al. 2017).

These tumors are usually slow-growing, and the clinical course may be asymptomatic to the point of acute complications. Manifestations of meningioma are

non-specific and usually related to the site and size of the tumor and follow pressure near the cerebral tissue (Gitto et al. 2018; Zhang et al. 2017). Typically, cephalgia and signs of intracranial hypertension are the first findings in these cases and it is infrequent for these tumors to cause a sudden unexpected death (Gitto et al. 2018; Kim et al. 2013; Zhang et al. 2017).

The following report describes two cases concerning sudden death due to intracranial meningiomas, including a review of the literature and an explanation of the different possible mechanisms of death.

Cases presentation

Case 1

A 47-year-old man was found unresponsive at his residence. No medical or surgery history was reported, and his relatives declared a history of intermittent chronic headaches, which became worse a few days before death, and was unresponsive to symptomatic therapy.

A judicial autopsy was ordered. At the external examination, the body was that of a medium-build male, 182 cm tall, and 81 kg. There was no external evidence of violence or trauma. At necropsy, the heart weighed 270 g, and no pathological findings were observed in coronary arteries or in myocardial sections. Lungs were congestive and edematous. The examination of the remaining abdominal organs did not show any specific lesion.

The brain was voluminous and weighed 1725 g, showing massive edema with severe flattening of the gyri. In the anterior cerebral fossa and facing the ethmoidal bone, there was a gray firm mass, attached to the dura, 6×4cm in size, weighing 65g (Fig. 1). Examination of the

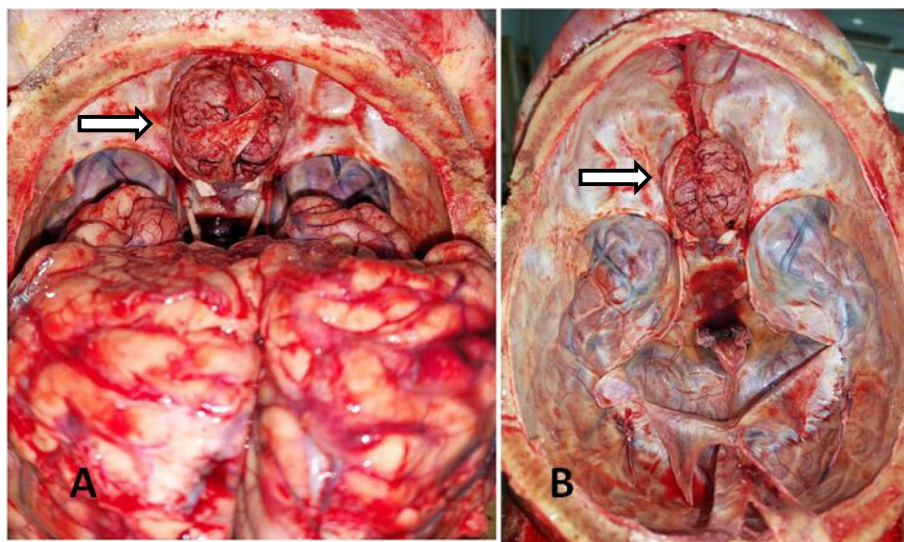


Fig. 1 Meningioma attached to the dura. **A** Before removing the brain **B** after removing the brain

cerebrum revealed a depressed area at the level of the inferior surface of the frontal lobes, corresponding to a compression of the tissues by the tumor. The cut sections of this brain show obliteration of the lateral ventricles by edema with no other focal areas of pathological changes. The remaining organs were unremarkable. This mass was taken for histopathologic analysis as well as samples from all the organs. Blood, urine, and gastric samples were taken for toxicological analysis. Histology of the brain tumor showed fibrotic stroma features consistent with a meningioma (Fig. 2). Pathologic examination of the other samples did not show abnormalities. Postmortem toxicology analysis was negative. The forensic doctor concluded a sudden death due to intracranial hypertension secondary to a meningioma of the anterior cranial fossa.

Case 2

A 62-year-old male, with no medical or surgical history of pathologies particularly no history of convulsion or epilepsy, was discovered dead in his bed. An autopsy was ordered by judicial authorities.

Questioning his relatives revealed that the deceased was complaining of chronic headaches and that he had experienced a sudden onset of brief loss of consciousness with occasional and recurrent vertigo a few days before his death leading him to consult a general physician. An imaging study was conducted 1 day before the survival of death, and the deceased was discharged with a date to retrieve the full report afterward.

External examination revealed a frothy foam on the nostrils with a bit on the tongue. No injuries were detected. The victim's height is 1.74 m tall, and his weight is 79 kg. At autopsy, the heart weighed 326 g, and no pathological findings were observed in coronary arteries. The myocardial sections showed no identified ischemic lesion and the left ventricular and septal wall thickness were 1 cm.

The right and left lungs weighed 510 g and 480 g, respectively, and were congestive and edematous. The cerebral vessels, carotid, and pulmonary arteries were with no pathological findings. The examination of abdominal organs did not show any specific lesion. The bladder was empty.

The cranial vault was intact. Removing the brain from the cranial cavity revealed a large cauliflower-like mass which was irregular, pedunculated, with a lobulated external appearance, attached to the dura at the level of the temporal area, 5.5 × 3 cm in size, 56 g in weight (Fig. 3).

Upon sectioning, the mass displayed focal hemorrhage. The brain weighed 1790 g. It was swollen and showed massive edema. The gyri are also flattened consistent with the massive edema. This mass was taken for histopathologic analysis as well as samples from all the organs. Blood, urine, and gastric samples were taken for toxicological analysis. Histopathology of the suspected brain mass showed typical features of meningioma. Microscopic examination of lung samples, myocardium, and the other samples did not show abnormalities.

Postmortem toxicology analysis was negative. Reviewing the brain MRI realized before death, the meningioma was seen in the left temporal area with a visible direct compression of the cerebral parenchyma (Fig. 4).

Given the autopsy findings of tongue biting, bladder emptiness, the presence of a cerebral tumor, and the temporal location of the mass, the hypothesis of convulsion before death was raised. Death was attributed to presumed seizure as a consequence of temporal meningioma.

Discussion

Meningioma is among the most frequent tumors of the central nervous system (Kim et al. 2013). They are observed most frequently in the following locations: convexity (lateral area of hemispheres) (20–37%), parasagittal (13–22%), spine (7–12%), cranial base (43–51%), frontal area (10–20%), the area of sphenoid bone

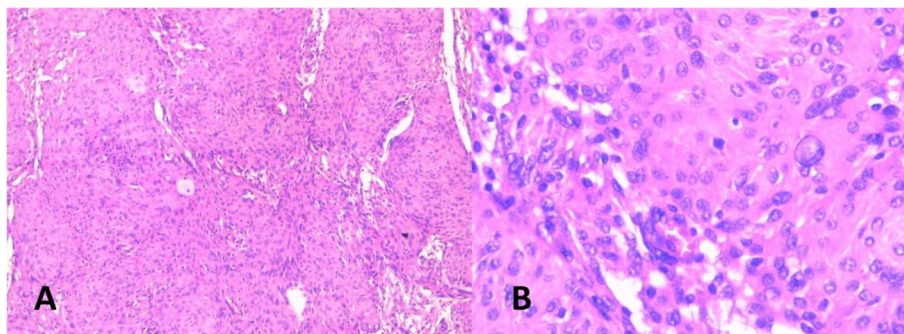


Fig. 2 Histological features of meningioma showing **A** lobulated architecture with meningotheelial whorls; H&Ex100 and **B** syncytial tumor cells with indistinct cell membranes, eosinophilic cytoplasm, and a round uniform nuclei with intranuclear pseudoinclusions; H&Ex400

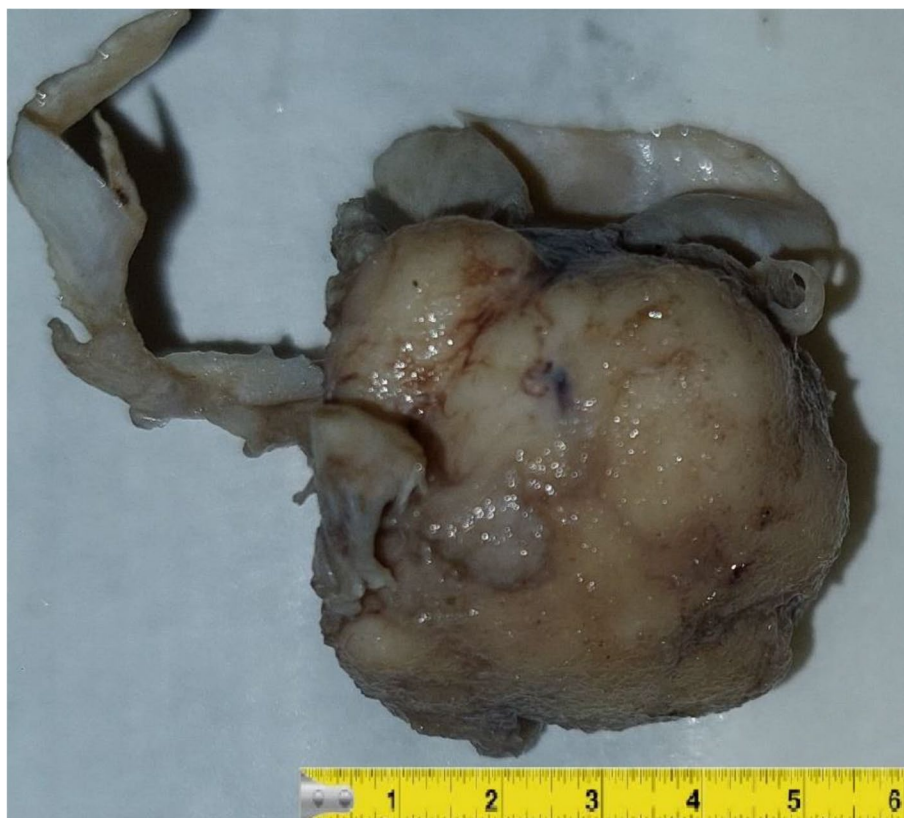

Fig. 3 Gross examination of meningioma in case 2 after formaldehyde fixation, measuring 5.5 × 3cm in size

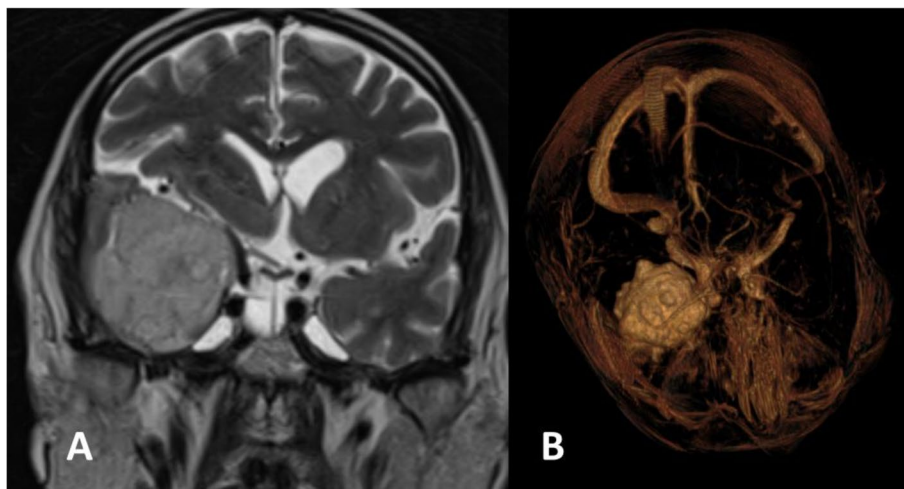


Fig. 4 MRI imaging showing the meningioma **A** coronal T2 **B** volume T1 with gadolinium injection

and middle cranial fossa (9–36%), posterior cranial fossa (6–15%), cerebellum tent (2–4%), the convexity of cerebellum (5%), cerebellopontine angle (2–11%), magal foramen (3%), and ectopic site < 1% (Huntoon et al. 2020; Magill et al. 2018; Voß et al. 2017).

These tumors are usually slow-growing and generate neurologic deficits due to either compression of adjacent parenchymatic and/or vascular structures or increased intracranial pressure (Li & Zhao 2009; Louis et al. 2007). The clinical manifestation is often non-specific and

usually is related to the tumor location (Menon et al. 2009). The most common clinical manifestations are as follows: cephalgia (33–36%); cranial nerves deficit (28–31%); seizures (16–24%); intellectual and cognitive alterations (14%); fatigue, dizziness, and loss of consciousness (9%); ataxia (6%); sensory disorder (5%); exophthalmos (2%); and syncopal episodes (1.0%) (Zouaoui et al. 2018).

Certain meningiomas may remain asymptomatic in 9% of cases (Magill et al. 2018; Zouaoui et al. 2018) which may be explained by the compensatory mechanisms that keep intracranial pressure levels within physiological limits. However, in other cases, during the decompensation phase, the patient's consciousness is lost, reflecting an increase in intracranial pressure. Herein, we report two cases that had experienced chronic cephalgia and recurrent vertigo before death with a brief loss of consciousness in case number two.

Although the vast majority of meningiomas are considered benign tumors, they can be accompanied by aggressive clinical behavior or serious consequences (Wiemels et al. 2010). In fact, many asymptomatic tumors are identified incidentally at autopsy (Gitto et al. 2018; Wiemels et al. 2010; Zhang et al. 2017). In such cases, death should not be attributed directly to the meningioma, as most incidentally detected meningiomas are known to be indolent (Nakamura et al. 2003). Therefore, to retain this hypothesis, a meticulous autopsy must be performed to rule out any other cause that may have been involved in the occurrence of death.

In the present report, we retained meningioma as the cause of death in both cases after having excluded other causes.

Cases of autopsied meningiomas assigned to sudden death are rare (Gitto et al. 2018; Kim et al. 2013; Rausing 1970). There were 172 meningiomas found by Rausing et al. (Rausing 1970) in a total of 11,793 necropsies, with only 11 of these 172 cases being directly related to the patient's death. Six cases of sudden unexpected death from intracranial meningioma were reported by Gitto et al. (2018) during a period between 1998 and 2016. According to our autopsy practice, we identified only two observations of fatal meningiomas, separated by 1 year. Thus, diagnosing incident meningioma as the cause of sudden death can be challenging (Gitto et al. 2018).

A wide variety of mechanisms of death were reported in the literature (Gitto et al. 2018; Kim et al. 2013; Rausing 1970; Yp et al. 2016). Raised intracranial pressure is the most common mechanism of death as a result of an intracranial expanding lesion, which causes acute manifestations including the development of cerebral herniation (Gitto et al. 2018; Rausing 1970). In the two present cases, the cerebrum was heavy and showed massive marked edema. The gyri were also severely

flattened in both cases, and the cut sections of the brain in case number 1 show obliteration of the lateral ventricles consistent with the massive edema. All these findings indicate the presence of intracranial hypertension.

The literature reported that 30 to 60% of patients with meningioma presented cerebral edema (Pistolesi et al. 2002; Yoshioka et al. 1999). Brain edema in meningioma seems to be a multifactor consequence. It is most often vasogenic and linked to an increased pial blood supply, new vessel formations, and enhanced vascular endothelial growth factor (VEGF) expression (Pistolesi et al. 2002; Yoshioka et al. 1999). In addition, the tumor itself may be a space-occupying lesion causing an increase in intracranial pressure (Gurkanlar et al. 2005) as particularly seen in the first case report. Compression of the cerebral parenchyma directly by the tumor may lead to decreased blood flow and local hypoxia, which results in cerebral edema and enlarged brain volume (Pistolesi et al. 2002). This is a common mechanism in voluminous meningiomas, producing endocranial edema which may exceed two to three times the tumor surface area and consequent intracranial hypertension (Gurkanlar et al. 2005; Pistolesi et al. 2002; Yoshioka et al. 1999).

Brain herniation, also known as cistern obliteration, is a deadly adverse effect of very high intracranial pressure that occurs when the brain shifts across structures within the skull as the falx cerebri, the tentorium cerebelli, and even through the foramen magnum. Because herniation puts extreme pressure on parts of the brain and thereby cuts off the blood supply to various parts of the brain, it is often fatal. In the cases that we report, there was no cerebral herniation at necropsy (Yoshioka et al. 1999).

Also, an increase in cerebral pressure may lead to sudden death from cardiac arrhythmia, particularly bradycardia. Meningiomas, when arising close to vital centers, may result in direct compression of vital nerve structures, the dysfunction of which may lead to sudden death from acute respiratory distress or cardiac arrhythmia (Gitto et al. 2018). According to the literature, skull base meningiomas are more frequently associated with sudden death than other locations owing to the existence of crucial structures traversing the occipital foramen (Gitto et al. 2018).

In the first reported case meningioma was located in the anterior cerebral fossa of the skull base. We noted signs indicative of endocranial hypertension including a large, swollen brain with obliterated ventricles, flattened gyri, and the presence of marked compression of tissue at the midline of the frontal lobes' base. The remaining organs were macroscopically and histologically with no abnormality. Toxicological analysis was negative. In the absence of other possible causes of death, we therefore attributed death in this case to intracranial hypertension in frontal meningioma.

Other mechanisms of sudden death occurrence have been reported in the literature, including malignant transformation, invasion, spontaneous intratumoral bleeding, or the occurrence of seizures (Gitto et al. 2018; Kim et al. 2013).

Seizures in meningioma patients were reported in 29% of 4709 patients according to Englot et al. (2016) and in 14% of 598 patients according to Hamasaki et al. (2013). As it is well reported that meningiomas of the anterior skull fossa have a large clinical presentation including vision trouble (54%), cephalgia (48%), anosmia (40%), convulsions (20%), and psychomotor disturbance, temporal lobe meningiomas are reported to present with an increasing risk of seizures (Lieu & Howng 1999; Marosi et al. 2008; Chen et al. 2017). Lieu and Howng have reported that temporal meningiomas have an increased risk of seizure occurrence than other locations and are responsible for 54.5% of epilepsy cases, followed by parietal ones with an incidence of 36.4% (Lieu & Howng 1999).

Epilepsy pathophysiology linked to cerebral tumors has a multifactorial approach and can be related to morphological, biochemical, and metabolic reasons (Ahmed et al., 2022).

Meningioma arises from the cells of the arachnoid cap and is generally a slow-growth tumor (Wiemels et al. 2010). Epileptogenicity may in part be the consequence of the peritumoral changes induced by this slow growth (Chen et al. 2017; Elbadry Ahmed et al. 2022). Differentiation of part of the brain's cortical surface can result in an epileptic zone, leading to a denervation hypersensitivity (Fang et al. 2013).

Morphological modifications of the peritumoral neocortex, including neural inefficient migration, and alterations in gap-glial junction pairing and synaptic vesicles, have also been suggested as factors contributing to the development of seizures (Van Diessen et al. 2013). On the other hand, chemical modifications occurring in the peritumoral space including a rise in glutamatergic neurons and a decrease in GABAergic neurons immunoreactive to somatostatin and the associated focal hypoxia caused by local compression of the tumor are considered to be underlying factors contributing to hyperexcitability and the lowering of the seizure threshold (Chen et al. 2017; Gurkanlar et al. 2005).

Edema in the peritumor cortex has also been extensively studied and reported to be the main predictor of seizure (Englot et al., 2016; Chaichana et al. 2013; Chen et al. 2017; Hamasaki et al. 2012; Xue et al. 2018). In a study conducted by Li et al., edema of the peritumor cortex >1cm was reported to be one of the identified risk factors for seizure occurrence in meningiomas (Li et al. 2020).

To better understand seizures in meningioma patients, a number of additional predictors of seizures have been

reported (Chen et al. 2017; Li et al. 2020; Chaichana et al. 2013). Across the literature, further studies suggest that larger-sized tumors are inherently prone to increased seizure risk. It is conceivable that bigger tumors may cause greater irritation and pressure on the peritumoral brain tissue. Related findings reported by Chen et al. found that meningiomas size greater than 3 cm, with peritumoral edema exceeding 1 cm, are increasingly associated with seizures (Chen et al. 2017).

The meningioma in case report number two was 5.5*3cm in size and was attached to the dura at the level of the temporal area. The brain was also swollen and had massive edema with flattening of the gyri. Tong biting was noted in the external examination and the bladder was empty at autopsy. These findings strengthened the hypothesis of epileptic seizure before death.

Also, it is worth noting that meningiomas are more prevalent in women, yet men are more susceptible to seizures. Numerous studies have identified that the male gender represents a risk factor for the occurrence of seizures (Chen et al. 2017; Englot et al. 2016; Xue et al. 2018). A potential association exists between the male gender and larger-sized meningioma, and increased edema (Chen et al. 2017; Hamasaki et al. 2012; Li et al. 2020). Thus, the male gender of case report number 2 supports the hypothesis of the eventual occurrence of the seizure. After eliminating other possible causes of death, we, therefore, attributed death in the second case to sudden death due to presumed seizure as a consequence of temporal meningioma.

Occasionally, meningiomas can bleed into the tumor (Gitto et al. 2018; Niiro et al. 2003), as documented on sectioning in the second case report, showing focal hemorrhage. The incidence of this event is ranging from 1.3 to 2.4% (Gitto et al. 2018). The exact mechanism of bleeding is not currently known, but there are several proposed hypotheses. The first assumption suggests that in well-vascularized meningiomas, the growth of the tumor causes neovessel stretching, compression, or invasion, leading to bleeding (Niiro et al. 2003). The second assumption is that resulting brain edema from the tumor induces venous blood flow obstruction of the tumor with a later infarction (Gitto et al. 2018; Niiro et al. 2003) and disruption of the neoplastic vessels resulting in bleeding.

Finally, meningiomas are generally benign neoplasms and their evolution to malignancy is extremely uncommon, with atypical and malignant forms only representing a minority of all meningiomas (5%) (Gitto et al. 2018). Such aggressive intracranial mass tends to spread to surrounding brain structures. Direct infiltration of critical nerve centers can result in sudden death and also in the development of a subsequent convulsive disorder caused by the tumor invasion of the brain tissue. In addition, the

invading lesion can erode the wall of the vessels, resulting in extensive intracranial hemorrhage and sudden death (Gitto et al. 2018; Huntoon et al. 2020).

Brain tissue infiltration by meningiomas has been recently explained by molecular mechanisms (von Spreckelsen et al. 2022). These mechanisms entail alterations in the cytoskeleton, interactions between cells and the extracellular matrix, and the involvement of growth factors and proteases. First, cytoskeleton alteration is a critical factor for cell migration, and overexpressed transgelin, immunohistochemical staining for cortactin and fascin-1, and upregulation of Rho-driven cytoskeletal rearrangements tend to promote high-grade meningioma invasion.

Adhesion to surrounding cells and the extracellular matrix (ECM) is a second crucial mechanism for migration and invasion. Integrins, cadherins, osteopontin, periostin (a ligand for CD44), and I-CAM1 (CD54) are known to play a role in adhesion-junction regulation in meningioma. The expression levels of these proteins appear to correlate with invasion and WHO grade. The role of growth factors and their receptors in the invasion of meningiomas remains unclear, and only VEGF expression appears associated with WHO grade. Finally, proteases have been reported to be involved in meningioma invasion. As a broad cluster of enzymes, proteases are able to degrade a large part of ECM components and/or different receptors.

In summary, these cases we report are interesting because of the rare presentation of sudden death as a result of meningiomas. As a matter of fact, the slow growth and general benignity of meningiomas may result in misdiagnosis, delayed diagnosis, or failure to properly treat these tumors, which can lead to fatal consequences. The clinicians must consider the lethal complications that can be associated with this tumor, especially the rapid increase in intracranial pressure secondary to the tumor growth.

Thus, through this report, we stress the importance of an imaging study as an early-stage examination in cases of persons presenting with chronic headaches, loss of consciousness, or sudden onset of epileptic seizure to earlier diagnose brain disease and to adopt early optimal management to avoid fatal outcomes. CT scan and especially MRI are the first elements of meningioma diagnosis (Ogasawara et al. 2021) when suspected.

Treatment for meningiomas is highly individualized and includes a combination of observation, surgical resection, radiotherapy, and rarely chemotherapy. For tumors that are small and asymptomatic (tumor diameter ≤ 3 cm), a wait-and-see approach is taken and followed with MRI scans until they become symptomatic or until their tumors are considered large enough to treat,

while complete surgical excision is the optimal treatment for symptomatic meningiomas, observation failure meningiomas, or large tumors that are anticipated to cause symptoms. Radiotherapy has become a first-line treatment for unresectable meningiomas, such as certain skull base meningiomas that have encased neurovascular structures. While systemic therapy is still under investigation, it is reserved for meningiomas that are recurrent or progressive that no longer respond to surgery and radiotherapy (Marosi et al. 2008; Ogasawara et al. 2021).

In case number two, an imaging study was performed one day prior to the individual's death; however, the diagnostic process for the meningioma was delayed. This delay was due to the patient being discharged with an appointment to receive the full report at a later date. In addition, the meningiomas in these two reported cases were large (> 3 cm) and symptomatic, which may justify the need for surgical intervention. Therefore, this report emphasizes the importance of early diagnosis and timely intervention when brain disease is suspected by clinicians to prevent fatal complications.

Conclusions

In conclusion, sudden death in meningioma is a rare event and its etiopathogenic features remain heterogeneous including essentially the rapid increase in intracranial pressure secondary to tumor growth. Forensic studies on this topic remain scarce and these evidences need to be addressed by further reports. These cases are considered noteworthy to be reported in the science community for their contribution to the knowledge that even benign tumors can lead to unexpected sudden death if undiagnosed. For the forensic community, we point out that only an exhaustive postmortem investigation and careful macroscopic examination, thorough for brain samples, are required to exclude neurological causes of sudden death.

As in clinical science, we point out that clinicians must consider the lethal complications that may be associated with such benign tumors. Thus, we emphasize the value of vigorous clinical and radiological investigations in patients presenting with any benign neurological symptom and the importance of earlier diagnosis and management of brain tumors, even benign ones, to prevent sudden decompensation with lethal complications.

Acknowledgements

None.

Authors' contributions

Dr. Mesrati and Dr. Brahim managed the publication searches and wrote the manuscript. Dr. Boussaid, Dr. Soiniya, and Dr. Mahjoub participated in the literature review. Dr. Ben Abdeljalil and Dr. Zakhama realized the histological examination of the brain tumors. Dr. Ben Nsir realized the interpretation

of the imaging study. Dr. Aissaoui revised the article critically for important intellectual content and performed the ultimate reviewing and editing for the submitted paper.

Funding

This research did not receive any specific grant from funding agencies in the public, commercial, or not-for-profit sectors.

Availability of data and materials

Data are available from the corresponding author on a reasonable request.

Declarations

Ethics approval and consent to participate

Ethical concepts were respected. Data were reported anonymously and had no bearing on the patient's care and there were no identifying images.

Consent for publication

Consent from the legal guardian of the deceased was obtained.

Competing interests

The authors declare that they have no competing interests.

Received: 11 August 2023 Accepted: 19 December 2023

Published online: 15 January 2024

References

- Chaichana KL, Pendleton C, Zaidi H, Olivi A, Weingart JD, Gallia GL, Lim M, Brem H, Quiñones-Hinojosa A (2013) Seizure control for patients undergoing meningioma surgery. *World Neurosurg* 79(3–4):515–524. <https://doi.org/10.1016/j.wneu.2012.02.051>
- Chen WC, Magill ST, Englot DJ, Baal JD, Wagle S, Rick JW, McDermott MW (2017) Factors associated with pre- and postoperative seizures in 1033 patients undergoing supratentorial meningioma resection. *Neurosurgery* 81(2):297–306. <https://doi.org/10.1093/neuros/nyx001>
- Elbady Ahmed R, Tang H, Asemota A, Huang L, Boling W, Bannout F (2022) Meningioma related epilepsy- pathophysiology, pre/postoperative seizures predictors and treatment. *Front Oncol* 12(July):1–11. <https://doi.org/10.3389/fonc.2022.905976>
- Englot DJ, Magill ST, Han SJ, Chang EF, Berger MS, M M (2016) Seizures in supratentorial meningioma: a systematic review and metaanalysis. *J Neurosurg* 124(6):1552–61. <https://doi.org/10.3171/2015.4.JNS142742>
- Fang S, Zhan Y, Xie YF, Shi Q, Dan W (2013) Predictive value of electrocorticography for postoperative epilepsy in patients with supratentorial meningioma. *J Clin Neurosci* 20(1):112–116. <https://doi.org/10.1016/j.jocn.2012.02.021>
- Gitto L, Bolino G, Cina SJ (2018) Sudden unexpected deaths due to intracranial meningioma: presentation of six fatal cases, review of the literature, and a discussion of the mechanisms of death. *J Forensic Sci* 63(3):947–953. <https://doi.org/10.1111/1556-4029.13626>
- Gurkanlar D, Er U, Sanli M, Özkan M, Sekerci Z (2005) Peritumoral brain edema in intracranial meningiomas. *J Clin Neurosci* 12(7):750–753. <https://doi.org/10.1016/j.jocn.2004.09.029>
- Hamasaki T, Yamada K, Yano S, Nakamura H, Makino K, Hide TI, Hasegawa Y, Kuroda JI, Hirai T, Kuratsu JI (2012) Higher incidence of epilepsy in meningiomas located on the premotor cortex: a voxel-wise statistical analysis. *Acta Neurochir* 154(12):2241–2249. <https://doi.org/10.1007/s00701-012-1511-1>
- Hamasaki T, Yamada K, Kuratsu JI (2013) Seizures as a presenting symptom in neurosurgical patients: a retrospective single-institution analysis. *Clin Neurol Neurosurg* 115(11):2336–2340. <https://doi.org/10.1016/j.clineuro.2013.08.016>
- Huntoon K, Toland AMS, Dahiya S (2020) Meningioma: a review of clinico-pathological and molecular aspects. *Front Oncol* 10(October):1–14. <https://doi.org/10.3389/fonc.2020.579599>
- Kim JH, Cho MH, Kim H, Gil R, Lee GY, Lee KB (2013) Sudden unexpected death caused by olfactory groove meningioma: a case report. *Korean J Leg Med* 37(4):208. <https://doi.org/10.7580/kjlm.2013.37.4.208>
- Li X, Zhao J (2009) Intracranial meningiomas of childhood and adolescence: report of 34 cases with follow-up. *Child's Nervous System* 25(11):1411–1417. <https://doi.org/10.1007/s00381-009-0949-9>
- Li X, Wang C, Lin Z, Zhao M, Ren X, Zhang X, Jiang Z (2020) Risk factors and control of seizures in 778 Chinese patients undergoing initial resection of supratentorial meningiomas. *Neurosurg Rev* 43(2):597–608. <https://doi.org/10.1007/s10143-019-01085-5>
- Lieu AS, Howng SL (1999) Intracranial meningiomas and epilepsy: incidence, prognosis and influencing factors. *Epilepsy Res* 38(1):45–52. [https://doi.org/10.1016/S0920-1211\(99\)00066-2](https://doi.org/10.1016/S0920-1211(99)00066-2)
- Louis DN, Ohgaki H, Wiestler OD, Cavenee WK, Burger PC, Jouvet A, Scheithauer BW, Kleihues P (2007) The 2007 WHO classification of tumours of the central nervous system. *Acta Neuropathol* 114(2):97–109. <https://doi.org/10.1007/s00401-007-0243-4>
- Magill ST, Young JS, Chae R, Aghi MK, Theodosopoulos PV, McDermott MW (2018) Relationship between tumor location, size, and WHO grade in meningioma. *Neurosurgical Focus* 44(4). <https://doi.org/10.3171/2018.1.FOCUS17752>
- Marosi C, Hassler M, Roessler K, Reni M, Sant M, Mazza E, Vecht C (2008) Meningioma. *Crit Rev Oncol Hematol* 67(2):153–171. <https://doi.org/10.1016/j.critrevonc.2008.01.010>
- Menon G, Nair S, Sudhir J, Rao BRM, Mathew A, Bahuleyan B (2009) Childhood and adolescent meningiomas: a report of 38 cases and review of literature. *Acta Neurochir* 151(3):239–244. <https://doi.org/10.1007/s00701-009-0206-8>
- Nakamura M, Roser F, Michel J, Jacobs C, Samii M, De Tribolet N, George B, Brem H, Weaver K, Kaye AH (2003) The natural history of incidental meningiomas. *Neurosurgery* 53(1):62–71. <https://doi.org/10.1227/01.NEU.0000068730.76856.58>
- Niir M, Ishimaru K, Hirano H, Yunoue S, Kuratsu J (2003) Clinico-pathological study of meningiomas with haemorrhagic onset. *Acta Neurochir* 145(9):767–772. <https://doi.org/10.1007/s00701-003-0089-z>
- Ogasawara C, Philbrick BD, Adamson DC. (2021) Meningioma: a review of epidemiology, pathology, diagnosis, treatment, and future directions. *Biomedicines* 9(3). <https://doi.org/10.3390/biomedicines9030319>
- Pistolesi S, Fontanini G, Camacci T, De Ieso K, Boldrini L, Lupi G, Padolecchia R, Pingitore R, Parenti G (2002) Meningioma-associated brain oedema: the role of angiogenic factors and pial blood supply. *J Neurooncol* 60(2):159–164. <https://doi.org/10.1023/A:1020624119944>
- Rausing ALF (1970) STUDY OF TEN YEARS It is difficult to estimate the absolute frequency of intracranial tumours. This applies in particular to meningioma with its variable and non-characteristic clinical manifestation. Many meningiomas do not produce symptoms until late. pp 102–110
- Van Diessen E, Diederich SJH, Braun KPJ, Jansen FE, Stam CJ (2013) Functional and structural brain networks in epilepsy: what have we learned? *Epilepsia* 54(11):1855–1865. <https://doi.org/10.1111/epi.12350>
- von Spreckelsen N, Kessler C, Brokinkel B, Goldbrunner R, Perry A, Mawrin C (2022) Molecular neuropathology of brain-invasive meningiomas. *Brain Pathol* 32(2):1–10. <https://doi.org/10.1111/bpa.13048>
- Voß KM, Spille DC, Sauerland C, Suero Molina E, Brokinkel C, Paulus W, Stummer W, Holling M, Jeibmann A, Brokinkel B (2017) The Simpson grading in meningioma surgery: does the tumor location influence the prognostic value? *J Neurooncol* 133(3):641–651. <https://doi.org/10.1007/s11060-017-2481-1>
- Vougiouklakis T, Mitselou A, Agnantis NJ (2006) Sudden death due to primary intracranial neoplasms. A forensic autopsy study. *Anticancer Res* 26(3 B):2463–2466
- Wiemels J, Wrensch M, Claus EB (2010) Epidemiology and etiology of meningioma. *J Neurooncol* 99(3):307–314. <https://doi.org/10.1007/s11060-010-0386-3>
- Xue H, Sveinsson O, Bartek J, Förander P, Skyman S, Kihlström L, Shafiei R, Mathiesen T, Tomson T (2018) Long-term control and predictors of seizures in intracranial meningioma surgery: a population-based study. *Acta Neurochir* 160(3):589–596. <https://doi.org/10.1007/s00701-017-3434-3>
- Yoshioka H, Hama S, Taniguchi E, Sugiyama K, Arita K, Kurisu K (1999) Peritumoral brain edema associated with meningioma. *Cancer* 85(4):936–944. [https://doi.org/10.1002/\(sici\)1097-0142\(19990215\)85:4%3c936::aid-cnrcr23%3e3.0.co;2-j](https://doi.org/10.1002/(sici)1097-0142(19990215)85:4%3c936::aid-cnrcr23%3e3.0.co;2-j)

- Yp RB, Sh R, Sh MB, Shetty HP (2016) Meningioma - a cause of sudden death. *Int J Med Toxicol Forensic Med* 6(1):47–49
- Zhang S, Zhang J, Chen J, Ai X, He X (2017) Frontal intradiploic meningioma with progressive intracranial invasion. *Medicine (United States)* 96(34). <https://doi.org/10.1097/MD.0000000000007903>
- Zouaoui S, Darlix A, Rigau V, Mathieu-Daudé H, Bauchet F, Bessaoud F, Fabbro-Peray P, Trétarre B, Figarella-Branger D, Taillandier L, Loiseau H, Bauchet L (2018) Descriptive epidemiology of 13,038 newly diagnosed and histologically confirmed meningiomas in France: 2006–2010. *Neurochirurgie* 64(1):15–21. <https://doi.org/10.1016/j.neuchi.2014.11.013>

Publisher's Note

Springer Nature remains neutral with regard to jurisdictional claims in published maps and institutional affiliations.

Submit your manuscript to a SpringerOpen[®] journal and benefit from:

- ▶ Convenient online submission
- ▶ Rigorous peer review
- ▶ Open access: articles freely available online
- ▶ High visibility within the field
- ▶ Retaining the copyright to your article

Submit your next manuscript at ▶ [springeropen.com](https://www.springeropen.com)
