

CASE REPORT

Open Access



# Penetrating two stab to the throat, survival time and physical mobility: a suicide case and literature review

Cemil Çelik<sup>1\*</sup>, Tuba Akkuş Çetinkaya<sup>1</sup>, Uğur Ata<sup>2</sup>, Murat Kamalak<sup>1</sup> and Naile Esra Saka<sup>2</sup>

## Abstract

**Background** It is difficult to pinpoint the manner of death in cases of death due to sharp force injuries where injury patterns resemble one another. Other issues that might arise include physical mobility and survival time after injury. Within the scope of this case, a 53-year-old male suicide with findings suggestive of homicide is presented, along with research on the nature of sharp neck injuries, survival time, and movement after injury.

**Case presentation** Thanks to the surveillance camera video that captured a significant portion of the occurrence, it was determined that the incident in the case that was presented, which had two perforations of the larynx, was suicide. At first appearance, this case could be assumed to be homicidal. Due to the injury, the victim could only walk around 300–350 m. The victim had a 4-h average survival time.

**Conclusions** In general terms, the survival time according to the injury sites in the neck can be listed for a person (if the wound sizes are close to each other) as follows: injury causing vagal stimulation < arterial injury with severe blood loss < venous injury with blood loss < airway injury causing aspiration and respiratory failure.

**Keywords** Acting capability, Sharp force, Neck, Case report, Stab

## Background

The rate of all suicide cases resulting from sharp-force injury is 1.91–3%. Males are more likely to sustain sharp force neck injuries during suicide (Stassi et al. 2021; Lupi Manso et al. 2021). Although it can be observed at any age, it is predominantly seen >30 years of age (Lupi Manso et al. 2021; Biétry et al. 2015; Terranova et al. 2020; Krywaczyk and Shapiro 2015). It was stated that the thorax, upper limbs, abdomen, and anterior neck were the parts of the body most frequently affected in suicide cases. In suicides, neck injuries range from 17 to

34% (Lupi Manso et al. 2021; Terranova et al. 2020; Krywaczyk and Shapiro 2015; De-Giorgio et al. 2015).

Exsanguination due to vessel injuries, particularly those to the carotid artery or jugular vein, asphyxiation due to blood aspiration in the respiratory tract, air embolism due to the opening of one or both jugular veins (external and internal), acute central cardiac arrest due to lesions of the medulla oblongata or upper cervical spinal cord (rarely, in very deep lesions, usually caused by stabbing), and vasovagal inhibition, or delayed complications are some of the causes of death following neck wounds with sharp force (Rao, 2015; Pakarinen et al. 2006; Bagheri et al. 2008; Vrinceanu et al. 2018; Shetty et al. 2009; Fracasso and Karger 2006; Barranco et al. 2018; Patel 1998).

In addition to determining the manner of death, forensic pathologists are often required to provide an opinion on the possible physical activity and probable survival time of an injured victim (Sauvageau et al. 2006). Without the evidence of the video recording, it is actually

\*Correspondence:

Cemil Çelik  
cemilcelik89@hotmail.com

<sup>1</sup> Council of Forensic Medicine, Forensic Medicine Branch Office, Kahramanmaraş, Turkey

<sup>2</sup> Department of Forensic Medicine, Tekirdağ Namik Kemal University, Tekirdağ, Turkey

impossible to determine the physical mobility capacity and precisely the survival time but rather a range of time (Sauvageau et al. 2006; Franchi et al. 2016). In fact, the case presented here focuses on the survival time and physical mobility after throat injuries rather than the manner of death. The term used in the study as “physical mobility after an injury” is also referred to as “acting capability” and “movement after injury” in the literature. The keywords “survival time, physical mobility, acting capability, movement after injury, sharp force, neck, throat, larynx” were entered into Google Scholar and PubMed databases, and studies on survival time and physical mobility after sharp force neck injuries were collected. We also carried out a “snowball” search by searching the reference lists of the full texts for additional studies and using Google Scholar to identify and screen studies citing them (Fig. 1). Because studies on forensic pathology mainly focused on the manner of death, studies on survival time and physical mobility after neck injury were very limited. Case reports from surgical clinics were also reviewed and included in this study.

Based on video surveillance camera footage that captured a significant portion of the scene during the fatal injury, an unusual suicide case due to stab wounds is presented. The aim of the current case is to discuss with the literature how the type of injuries sustained and the likelihood of survival and physical activity capacity.

**Case presentation**

**Clinical case history**

A 53-year-old male was reported to have committed suicide by self-inflicted neck stabbing with the 13.2-cm-long, single-edged knife in a temporary refuge center equipped with a video surveillance system that recorded

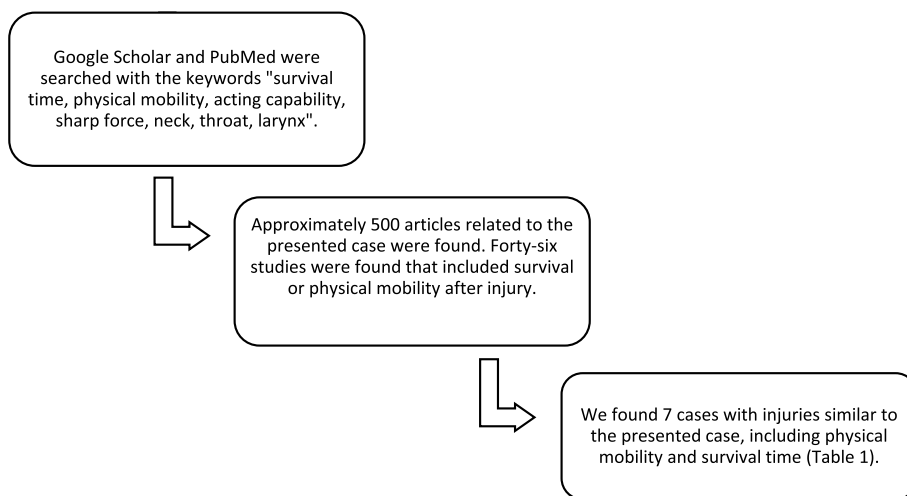
most of the scene. His wife told the police that he had been treated for a psychiatric disorder. The victim was a right-handed person. According to the emergency department’s records, it was reported that cardiopulmonary resuscitation was applied to the man who had a hesitation mark in his left wrist, a penetrating injury in his throat and swallowed a battery, and received cardiopulmonary arrest during transfer to the hospital. Despite receiving roughly 35 min of 2nd time cardiac resuscitation, the patient passed away (at 12:03 pm) after the battery was removed through endoscopy in the hospital.

**Autopsy findings**

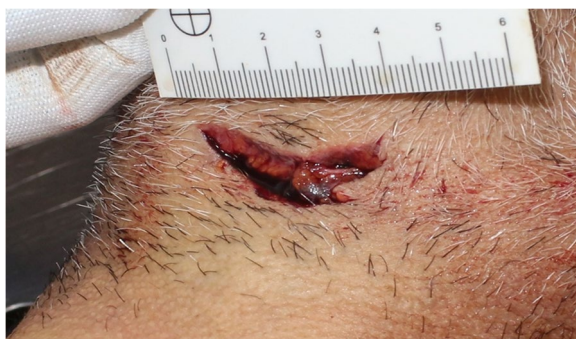In the external examination, an irregularly shaped stab wound complex of approximately 3.8 cm in linear length with clean margins, sharp, and blunt angles was discovered on the throat of the victim (Fig. 2). On the inner side of the left wrist, there was an incision (hesitation wound) measuring 3.5 cm in length and 0.8 cm in depth; however, it did not incapacitate the patient (Fig. 3).

A complete autopsy was performed in this case, with the neck spared during the en bloc removal of the organs. The lungs, brain, liver, spleen, and kidneys were pale and indicative of severe bleeding. Blood aspiration findings with a spotty pattern subpleural were found on the lungs (Fig. 4). His stomach was empty. The other body structures had no significant findings. To make it easier to dissect the bloodless areas, the neck was dissected last. The vessels, nerves, larynx, trachea, cricoid, thyroid, hyoid, pharynx, and ribbon muscles of the neck were carefully dissected to examine the wounds. The major vessels and nerves were intact.

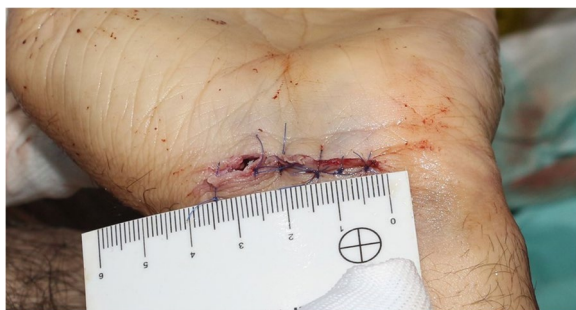Internal examination revealed two penetrating stab wounds to the larynx, although the skin injury was



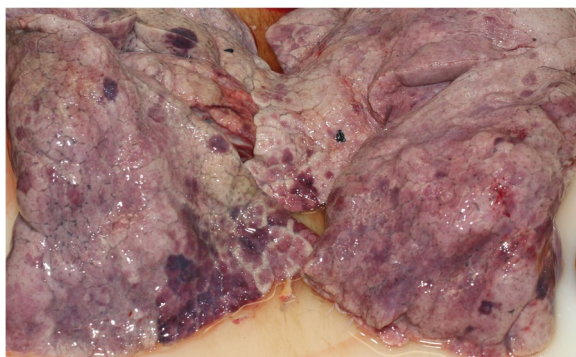
**Fig. 1** Flow diagram of literature review



**Fig. 2** A stab wound complex representing two intersecting stab wounds on the larynx. After stabbing himself in the throat, the deceased pulled the knife back and stabbed himself a second time



**Fig. 3** The hesitation mark without incapacitation



**Fig. 4** Blood aspiration findings with a spotty pattern subpleural on the lungs

complex-conjunct. One oblique 2.5-cm-long wound was visible in the region above the hyoid bone. The penetration occurred above the hyoid bone, going upwards and backward on the anterior side of the neck, and the radix linguae was sliced obliquely; the injury proceeded to the hypopharynx, and it ended anterior of the corpus of the third cervical vertebra. The second wound was located

in the region of the thyrohyoid membrane between the thyroid cartilage and the hyoid bone. We observed that the oblique, penetrating stab injury on the thyrohyoid membrane, which was 3.5 cm long, continued cutting in the epiglottis root, going upwards and backward on the anterior of the neck, the right and left superior horns of the thyroid cartilage, and perforated the esophagus and ended anterior of the corpus of the 4th cervical vertebra, respectively. The deceased had no significant carotid or venous injuries, although there were some minor venous injuries.

#### Toxicological and biological analysis

After systemic toxicological analysis, no toxic substances such as alcohol, stimulants, or narcotics were detected in blood, vitreous humor, and urine. Paroxetine (261, 01 ng/ml) was detected at the therapeutic level in the blood. The knife used was single edged with a 13.2-cm blade and a pointed tip. It was determined that the DNA profile in the biological swap sample taken from the blood on the handle and blade of the knife was compatible with that of the deceased.

#### Surveillance video analysis

In the temporary refuge center's surveillance video footage, we observed that the deceased took a knife out of his right pocket and placed it under his armpit at 08:46:11 pm while walking, and he was out of the camera's field of view at 08:46:29 pm. At 08:59:01 pm, he re-entered to the camera's field of view, was having trouble walking, was holding a knife in his right hand that was covered in blood, and he left the camera's field of view at 08:59:20 pm. At 09:00:14 pm, he re-entered the camera's field of view, walked with difficulty, fell to the ground at 09:00:34 pm, got up from the ground at 09:00:45 and continued walking with difficulty, fell to the ground once more at 09:00:59 pm and continued walking by getting up from the ground with difficulty at 09:01:30 pm, fell down again at 09:01:45 pm, got up at 09:02:21 pm and continued walking, and fell again at 09:02:35 pm. At 09:02:59 pm, he struggled to stand and walked toward the container where he lived in; at 09:03:26, he was no longer in the camera's frame of vision. It was observed that no one was seen around or close to the deceased on the cameras. It was assumed that the deceased stabbed himself between 08:46:29 pm and 08:59:01 pm. When the movements of the case were analyzed, it was understood that he was moving toward his house with semi-conscious movements by waving his hands and falling down and getting up. According to the scene investigation report, the incident occurred 300–350 m away from his house, and the distance walked there was covered in blood spatter with drip patterns. The deceased was taken to the hospital by

ambulance, and he died ~4 h after the incident despite the treatments provided there.

In this case, autopsy findings showed double penetrating throat injury over the anterior of the neck, obliquely placed at the level of laryngeal prominence in the midline, extending deep up to the vertebrae. We concluded that the cause of death was asphyxia due to blood aspiration and hemorrhagic shock due to slow bleeding. Surveillance video recordings verified suicide. The investigation concluded that the injuries were intentionally self-inflicted, and the manner of death was suicide.

## Discussion

### The manner of death

Sharp force wounds on accessible parts of the body, the absence of bone or cartilage wounds, the presence of hesitation wounds, a history of mental illness, and a single neck stab wound all increase the risk of suicide (Stassi et al. 2021; Lupi Manso et al. 2021; Terranova et al. 2020; Krywaczyk and Shapiro 2015; Brunel et al. 2010). The presence of defensive or violence-associated traumatic wounds is predictive of homicide (Brunel et al. 2010). Homicide is predicted by injuries to the head, limbs, hands, nape, or back, whereas wounds located solely at the anterior parts of the trunk, neck, or forearms are predictive of suicide (Lupi Manso et al. 2021; Brunel et al. 2010; Yadav et al. 2016).

The characteristics of neck self-cuts are described as being localized on the anterior surface or lateral (right or left, depending on the victim handedness) moving toward the anterior surface, with an oblique, downward inclination, or less frequently horizontal (Stassi et al. 2021). Victims with typical suicidal cut throats may grasp the handle of the weapon oblique to the palm with the elbow bent at 90° to the body, determining an oblique orientation to the wound. According to forensic experts, most suicide cut throats are oblique, starting on the upper part of the left or right side (depending on the victim handedness) of the neck, just below the angle of the jaw, and finishing on the opposite side. The incision is deeper at first, then becomes shallower as it moves along, terminating with a tail as it crosses the throat (Shetty et al. 2009; Yadav et al. 2016). The effectiveness of a penetrative stabbing requires the exertion of the more significant strength possible, which depends on the victim's strength, the resistance offered by the tissues and organs of the neck, the penetrative capability of the sharp force, and the range of motion of the wrist. Therefore, a more natural and effective grip on the sharp force is most likely expected to produce a horizontally or slightly obliquely oriented wound (Stassi et al. 2021). In the present case, two penetrating wounds to the larynx had by the intersection of two oblique stab wounds in different directions.

In homicidal cases, stab wounds are most frequently localized to the lateral area of the neck and a vertical orientation (Stassi et al. 2021; Barranco et al. 2018). Homicide wounds are deeper, extending to the vertebra due to the excessive use of force by the assailant (Yadav et al. 2016). Notches on the vertebrae that require a significant amount of effort and damage to the medulla spinalis are said to be more indicative of a potential homicide in cut throat instances than unidirectional or bidirectional cuts (Rao, 2015; Brunel et al. 2010). In addition, in cases of homicide with cut throats, most wounds were oriented from left to right, perhaps because the right hand is more dominant in most people (Rao, 2015). However, these assumptions in the literature refer to cases of the cut throats rather than penetrative throat injuries. Depending on the length of the weapon used, it is predicted that a penetrative injury may extend to the vertebrae. This case differs from typical suicidal injuries caused by stab wounds in that the neck was twice penetrated, there was no hesitation cutting on the neck, and there were notches on the vertebrae.

The distinction between homicide and suicide requires analysis of autopsy results and comparison with additional findings from the death scene investigation, such as bloodstain pattern analysis (Lupi Manso et al. 2021; Terranova et al. 2020; De-Giorgio et al. 2015; Brunel et al. 2010). Given the circumstantial evidence, including the existence of a video recording, the absence of defense wounds on the victim's body, the presence of a hesitation incision on the inside of the victim's left wrist, and the presence of fingerprints of the deceased on the weapon, it is clear that this case was a deliberate suicidal double penetrating injury to the throat. In complex suicides, two or more methods are applied either simultaneously or one after the other. In the present case, the battery swallowing, the hesitation mark on the wrist, and penetrating stab to the throat indicate a complex suicide.

### Survival time

The survival time and physical activity after a fatal injury depend on many factors such as the mechanism, site, extent and severity of the injury, the physiological state, and blood loss. The amount of blood loss, whether internal or/and external, is the most crucial biological element determining death or survival (Sauvageau et al. 2006; Franchi et al. 2016; Cros et al. 2013).

In practice, only a rough estimate of survival time and physical activity potential is possible, except in cases where we have external data such as a video recording of the victim, or the injuries of brain stem or medulla oblongata (Engelgardt and Krzyżanowski 2018). Five parameters have been proposed as outcome predictors of sharp instrument lesions regarding post-injury physical



activity and survival time: the site of injury, the size of the wound, the number of lesions, amount of blood loss and cardiac tamponade (Sauvageau et al. 2006). It is generally considered that arterial lesions will lead to death quicker than venous ones, as will do the large-vessel injuries compared to smaller vessels (Sauvageau et al. 2006). Quan et al. (2010) reported that blunt injuries with massive hemorrhage and sharp instrument injuries to the heart or a proximal major vessel (thoracic aorta or subclavian/carotid artery) were both associated with survival time-dependent increases in erythropoietin (EPO) levels within approximately 6 h (Quan et al. 2010). However, this study is the only one pioneering in the literature and the prospective use of EPO in postmortem should be further investigated. More significant results can be obtained in cases with isolated neck injury presenting to the emergency department. Because there is blood loss and shock on one side of the death mechanism, postmortem studies on their markers may guide the estimation of survival time.

Studies in the literature handle cases of sharp force injuries to the neck in two ways: as fatalities and as hospitalizations. According to the study by Biétry et al. (2015), the injury to the upper airway is the primary life-threatening issue with sharp neck injuries with suicidal intent, and only small vessel injuries in the neck were discovered, with no fatal hemorrhagic issues. Although sharp neck injuries often appear to be severe at first, considering factors such as early intervention, stopping the bleeding, and securing the airways, some cases have a possibility of recovery as long as they are transferred to the emergency department. There are studies on traumatic penetrating neck injuries exist, and they generally address the management of the tracheal injuries in the case of an unstable airway. The primary foci are the direct damage to the airway, aspiration, and hemorrhage (Stassi et al. 2021; Biétry et al. 2015; Rao, 2015; Vrinceanu et al. 2018; Gupta et al. 2009; Alunni et al. 2020). It has been shown that the hospital mortality rates are almost zero with current treatments in cases admitted to the hospital due to neck injuries, particularly in penetrating neck injuries, with a suicide attempt (Pakarinen et al. 2006). If the vagus nerve and major vessels are not affected, even severe neck cuts appear to heal with medical care and are not immediately fatal (Ventura et al. 2010).

Additionally, penetrating stab type and a higher injury severity score are among the dominant indicators of complications and mortality in stab patients (Brunel et al. 2010; El-Sarnagawy et al. 2022). Large arterial vessel injury, e.g., cervical artery, is fatal within seconds to minutes (Engelhardt and Krzyżanowski 2018). It has been reported that the estimated survival time in 24 homicide cases with neck injury ranges from 5 to >180 (~%67 of

cases) min (Cros et al. 2013). The literature shows that most cases have a survival time until they are delivered to the emergency department.

In sharp neck injuries to suicidal intent, injuries of the important vascular structures are rare and the lesions are limited to the superficial area. One reason may be the protected location behind the sternocleidomastoid muscle (Biétry et al. 2015). The carotid arteries in suicide wounds are usually spared because they are drawn beneath the sternomastoid muscles due to hyperextension of the neck by the victim (Yadav et al. 2016). Bleeding is often tamponaded by the fascial layers of the neck (Bagheri et al. 2008).

Vascular injuries are the most common injuries associated with penetrating neck trauma, occurring in 40% of patients; 10% of these injuries involve the carotid artery. Penetrating injuries have a 10–30% mortality rate (Bagheri et al. 2008). In a case of penetrating splinter injuries of the larynx (both lateral walls) and thyroid gland, it was reported that the patient had little oozing, no dyspnea, or alteration of voice. In addition, in the stab injury to the right superior thyroid artery reaching all the way to the pharyngeal wall, it was stated that the patient exhibited active bleeding from the wound and features of hypovolemic shock (Gupta et al. 2009). In the patients who were brought to the emergency department while maintaining full consciousness with large stab wounds dividing their supraglottic regions from the glottis without vascular injury, it was reported that the patients were able to breathe through these cuts and survived (Ozlugedik et al. 2005; Kaya et al. 2013). A case of penetrating injury in the neck with multiple laryngeal fractures, hypopharyngeal, and esophageal lacerations from a powered knife was found 30 min later. According to reports, he was conscious, stable, and showing just minor signs of respiratory distress when he arrived at the hospital (Carvalho et al. 2021).

In the study by Zimmer et al. (1994), it is stated that a single throat cut with cut of the trachea has a 30-min survival time. The survival time of ~30 min in isolated tracheal injury appears to be at odds with the existing literature. According to the literature, tracheal injury victims have a survival time until they reach the hospital. In the case of Zimmer et al. (1994), the tracheal injury was probably accompanied by a vascular injury that resulted in excessive bleeding.

In the presented case, it is clear from the video footage that two laryngeal perforations by the double stabbing provided a survival time of at least 4 h. There was no major vascular injury in the described wound tracks apart from “minor venous injury.” There was no indication of significant blood loss at the scene. This should be taken into consideration when describing the survival time and

**Table 1** The case features in sharp force injuries to the neck

Source	Sex/age	Injury localization	Survival time	Physical activity before collapse	Toxicology	Type of injury	Cause of death
The present case	M/53	The two perforation of both the larynx and the trachea	~4 hours	300–350 meters	Paroxetine (261, 01 ng/ml)	Stabbing	Asphyxia due to blood aspiration and hemorrhagic shock
Shetty et al. 2009	M/45	Laceration of the larynx and the left common carotid artery and bilateral external jugular vein	n/a <sup>a</sup>	Sudden collapse	negative	A cutting wound caused by sharp-edged knife	Hemorrhagic shock
Alunni et al. 2020	M/25	The perforation of both jugular veins and the trachea	At least 4 to 6 min.	~400 meters	negative	Stabbing	Hemorrhagic shock
Patel 1998	M/40	Soft tissue contusion over the carotid sheath	Seconds	Sudden collapse	negative	Screwdriver stabbing	Cardio-neurogenic inhibition associated with excessive stimulation of the vagus nerve
Barranco et al. 2018	M/38	Hematoma near the trunk of the vagus nerve and its branches	Seconds	Sudden collapse	BAC: 1.83 g/L	An incision on the left sternocleidomastoid	Fatal vagal inhibition and parasympathetic nervous system stimulation
Sauvageau et al. 2006	M/50	Right jugular vein perforation	~8 hours	Walking around and around the house	n/a <sup>a</sup>	A large incised wound caused by mirror fragments	Hemorrhagic shock
Fracasso and Karger 2006	F/31	Transection of the left common carotid artery and injuries of the internal jugular vein and the vagal nerve	~20 seconds	About 6 meters	BAC: 1.26 g/L	Puncture wounds caused by a broken goblet	Hemorrhagic shock
Yadav et al. 2016	M/-	The left anterior jugular vein	~5 hours	n/a <sup>a</sup>	n/a <sup>a</sup>	Cutting	Hemorrhagic shock

BAC blood-alcohol concentration, M male, F female

<sup>a</sup> Not available

ability to act following the injury. Case reports in the literature can be a guide to estimating of survival time based on the type and extent of injury (Table 1). Cases with similar injuries and no additional injuries are included in Table 1. In general terms, according to Table 1 and the literature, compared to the site of injury, the survival time can be for a person with a wound of a similar size as follows: injury causing vagal stimulation < arterial injury with severe blood loss < venous injury with blood loss < airway injury causing aspiration and respiratory failure. In addition, note that not all vagus nerve injuries result in abrupt collapse and death (Fracasso and Karger 2006; Lee et al. 2020).

### Physical mobility after an injury

In homicide cases, it is important to determine whether the victim could carry on fighting, run away, resist, or perhaps do someone an injury before eventual collapse and death. The ability to move depends on factors such as the type of injury, age, sex, physical traits, and diseases (Engelgardt and Krzyżanowski 2018). The blood spatter patterns at the scene can provide strong evidence for reconstructing the event and movement at the time of death.

The activity is affected by the extent of vascular injury because it alters the rate of blood loss. The case presentations are important in terms of obtaining ideas for physical mobility (Table 1). According to the literature, a person with a cut carotid can move at least 10 m (Savageau et al. 2006; Karger et al. 1999). A 30-year-old man of average weight who committed suicide at home by cutting his throat had a right carotid communis artery, trachea, and jugular external vein injury. It is stated that there are blood traces in the house 6–7 m away (Solarino et al. 2011). A 46-year-old woman of average weight who committed suicide by cutting her throat had a right jugular external vein injury with somewhat deep cutting. It was reported that the handbag of the deceased and a slightly blood-smearred single-edged kitchen knife were found in a shrubbery located 4–5 m below the deceased's position (Solarino et al. 2011).

Similar to the case of Alunni et al. (2020), in our case, the physical activity, which lasted for at least 4 min, was well documented, and he walked for at least 300–350 m despite having two perforations in his larynx. He also had two penetrating stab wounds on his neck, which raised the suspicion of homicide at first sight. Injuries of the major airways are not immediately lethal and do not lead to immediate incapacitation. The amount of blood that leaks into the bronchioles per unit of time and airway narrowing are likely to affect the survival time and mobility capacity after tracheal injuries.

According to the study by Thoresen and Rognum (1986), the degree of alcohol intoxication seems to have no effect on the capability to move and survival time. Likewise, it was stated in a different study with a smaller sample size that positive toxicological findings had no bearing on the connection and that the smaller sample size precluded the examination of each harmful substance (alcohol, drugs, etc.) (Cros et al. 2013). The other studies have shown that alcohol significantly impairs the immediate hemodynamic, metabolic, and inflammatory counterregulatory responses to hemorrhagic shock (Molina et al. 2013; Bilello et al. 2011). Toxicological substrates, such as alcohol and drugs, probably affect survival time and ability to move. To demonstrate this, however, large-scale research is required.

### Conclusions

The survival time and physical mobility after injury depend on the site of injury, number of lesions, amount of blood loss, patency of airways, and amount of blood aspiration in neck injuries. Therefore, during the autopsy procedure, all injuries and findings that can have an impact on the deceased's capacity to move and surviving time should also be reviewed in addition to the cause of death.

It should be taken into consideration that cases with penetrating tracheal/laryngeal injury to the neck can travel at least 300–350 m and have a survival time of up to approximately 4 h. Physical mobility and survival time decrease as the severity of the injury increases. In addition, it should be kept in mind that physical activity after injury will shorten the survival period. A case-by-case evaluation will yield more predictable results.

A thorough study of the crime scene, autopsy results, and witness accounts are necessary to determine the manner of death. In case reports in which the manner of death is evaluated, which we have noticed to be lacking in the literature, examining the survival time and physical mobility after injury will increase the knowledge on these issues.

### Acknowledgements

We would like to thank for their contribution to the Council of Forensic Medicine. A part of this study was presented as a poster paper at the 2nd International Istanbul Health Sciences Congress on 9–10 June 2023.

### Authors' contributions

ÇÇ: performed the autopsy, did the literature search, and prepared the draft manuscript. TAÇ: performed the autopsy, shared some material. MK: supervised the autopsy and reviewed the manuscript. UA and NES: searched literature, revised the manuscript. All authors read and approved the final manuscript.

### Funding

This research did not receive any specific grant from funding agencies in the public, commercial, or not-for-profit sectors.

### Availability of data and materials

Not applicable.

## Declarations

### Ethics approval and consent to participate

Not applicable.

### Consent for publication

Permission was obtained from The Council of Forensic Medicine with the date 06.21.2021 and number 21589509/2021/785 and Helsinki Declaration rules were followed to conduct this study.

### Competing interests

The authors declare no competing interests.

Received: 6 September 2023 Accepted: 27 November 2023

Published online: 18 December 2023

## References

- Alunni V, Cabusat-Mailliet C, Quatrehomme G (2020) A case of multiple self-inflicted stab wounds of the neck captured on surveillance video. *J Forensic Sci* 65(4):1368–1370. <https://doi.org/10.1111/1556-4029.14295>
- Bagheri SC, Khan HA, Bell RB (2008) Penetrating neck injuries. *Oral Maxillofac Surg Clin North Am* 20(3):393–414. <https://doi.org/10.1016/j.coms.2008.04.003>
- Barranco R, Molinelli A, Ventura F (2018) An unusual murder: vasovagal death from atypical stabbing to the neck. *Am J Forensic Med Pathol* 39(4):367–369. <https://doi.org/10.1097/PAF.0000000000000429>
- Biétry D, Exadaktylos A, Müller T, Zbären P, Caversaccio M, Arnold A (2015) Sharp neck injuries in suicidal intention. *Eur Arch Otorhinolaryngol* 272(12):3825–3831. <https://doi.org/10.1007/s00405-014-3471-y>
- Bilello J, McCray V, Davis J, Jackson L, Danos LA (2011) Acute ethanol intoxication and the trauma patient: hemodynamic pitfalls. *World J Surg* 35(9):2149–2153. <https://doi.org/10.1007/s00268-011-1191-7>
- Brunel C, Fermandian C, Durigon M, Grandmaison GL (2010) Homicidal and suicidal sharp force fatalities: autopsy parameters in relation to the manner of death. *Forensic Sci Int* 198(1–3):150–154. <https://doi.org/10.1016/j.forsciint.2010.02.017>
- Carvalho M, Mourão M, Silva M et al (2021) Self-inflicted powered knife penetrating neck injury - a case report. *Port J Otorhinolaryngol Head Neck Surg* 59(3):315–319. <https://doi.org/10.34631/sporl.927>
- Cros J, Alvarez JC, Sbidian E, Charlier P, Lorin G (2013) Survival time estimation using injury severity score (ISS) in homicide cases. *Forensic Sci Int* 233(1–3):99–103. <https://doi.org/10.1016/j.forsciint.2013.08.026>
- De-Giorgio F, Lodise M, Quaranta G, Spagnolo AG, d'Alaja E, Pascali VL et al (2015) Suicidal or homicidal sharp force injuries? A review and critical analysis of the heterogeneity in the forensic literature. *J Forensic Sci* 60(1):97–107. <https://doi.org/10.1111/1556-4029.12673>
- El-Sarnagawy GN, Shama MA, Helal NE (2022) Characteristics and outcomes of homicidal and accidental stab wounds in emergency hospitals: a medico-legal comparative study. *Leg Med (Tokyo)* 58:102075. <https://doi.org/10.1016/j.legalmed.2022.102075>
- Engelgardt P, Krzyżanowski M (2018) Evaluation of survival time and acting capability after fatal injuries based on the type and extent of injuries. *Arch Med Sadowej Kryminol* 68(1):32–45. <https://doi.org/10.5114/amsik.2018.75945>
- Fracasso T, Karger B (2006) Two unusual stab injuries to the neck: homicide or self-infliction? *Int J Legal Med* 120(6):369–371. <https://doi.org/10.1007/s00414-005-0052-z>
- Franchi A, Kolopp M, Coudane H, Martrille L (2016) Precise survival time and physical activity after fatal left ventricle injury from sharp pointed weapon: a case report and a review of the literature. *Int J Legal Med* 130(5):1299–1301. <https://doi.org/10.1007/s00414-016-1338-z>
- Gupta PD, Verma RN, Anand V (2009) Two cases of penetrating injury of the neck. *Med J Armed Forces India* 65(4):371–372. [https://doi.org/10.1016/S0377-1237\(09\)80106-8](https://doi.org/10.1016/S0377-1237(09)80106-8)
- Karger B, Niemeyer J, Brinkmann B (1999) Physical activity following fatal injury from sharp pointed weapons. *Int J Legal Med* 112(3):188–191. <https://doi.org/10.1007/s004140050230>
- Kaya KH, Koç AK, Uzut M, Altıntaş A, Yeğın Y, Sayın I et al (2013) Timely management of penetrating neck trauma: report of three cases. *J Emerg Trauma Shock* 6(4):289–292. <https://doi.org/10.4103/0974-2700.120382>
- Krywanczyk A, Shapiro S (2015) A retrospective study of blade wound characteristics in suicide and homicide. *Am J Forensic Med Pathol* 36(4):305–310. <https://doi.org/10.1097/PAF.0000000000000188>
- Lee YJ, Kim HJ, Kang HT, Lee SW, Park KN (2020) Clinical characteristics of neck stab wounds: a single-institute retrospective study of 89 patients. *Korean J Otorhinolaryngol-Head Neck Surg* 64(4):247–251. <https://doi.org/10.3342/kjorl-hns.2019.00395>
- Lupi Manso N, Ribeiro IP, Inácio AR (2021) Sharp force fatalities: differentiating homicide from suicide through a retrospective review (2012–2019) of autopsy findings in Lisbon (Portugal). *Forensic Sci Int* 327:110959. <https://doi.org/10.1016/j.forsciint.2021.110959>
- Molina PE, Sulzer JK, Whitaker AM (2013) Alcohol abuse and the injured host: dysregulation of counterregulatory mechanisms review. *Shock* 39(3):240–249. <https://doi.org/10.1097/SHK.0b013e318285b86d>
- Ozlugedik S, Acar A, Tuncel U, Akmansu H, Unal U, Ozcan M et al (2005) Unusual penetration trauma of the supraglottic larynx. *J Trauma* 58(2):401–403. <https://doi.org/10.1097/01.ta.0000056166.55328.7a>
- Pakarinen TK, Leppäniemi A, Sihvo E, Hiltunen K, Salo J (2006) Management of cervical stab wounds in low volume trauma centres: systematic physical examination and low threshold for adjunctive studies, or surgical exploration. *Injury* 37(5):440–447. <https://doi.org/10.1016/j.injury.2006.01.044>
- Patel F (1998) Vasovagal death from screwdriver stabbing of the neck. *J Clin Forensic Med* 5(4):205–206. [https://doi.org/10.1016/s1353-1131\(98\)90136-5](https://doi.org/10.1016/s1353-1131(98)90136-5)
- Quan L, Zhu BL, Ishikawa T, Michiue T, Zhao D, Ogawa M, Maedaet M (2010) Postmortem serum erythropoietin level as a marker of survival time in injury deaths. *Forensic Sci Int* 200(1–3):117–122. <https://doi.org/10.1016/j.forsciint.2010.03.040>
- Rao D (2015) An autopsy study of 74 cases of cut throat injuries. *Egypt J Forensic Sci* 5(4):144–149. <https://doi.org/10.1016/j.ejfs.2014.10.001>
- Sauvageau A, Trépanier JS, Racette S (2006) Delayed deaths after vascular trauma: two cases. *J Clin Forensic Med* 13(6–8):344–348. <https://doi.org/10.1016/j.jcfm.2006.06.008>
- Shetty BS, Padubidri JR, Bhandarkar AM, Shetty AJ, Shetty M (2009) "Atypical Suicidal" cut throat injury—a case report. *J Forensic Leg Med* 16(8):492–493. <https://doi.org/10.1016/j.jflm.2009.07.003>
- Solarino B, Buschmann CT, Tsokos M (2011) Suicidal cut-throat and stab fatalities: three case reports. *Rom J Leg Med* 19:161–166. <https://doi.org/10.4323/rjlm.2011.161>
- Stassi C, Mondello C, Baldino G, Benedetto F, La Corte F, Salamone I et al (2021) Unusual attempted suicide or covered attempted homicide? A neck stabbing case report and review of literature. *Int J Legal Med* 135(2):555–559. <https://doi.org/10.1007/s00414-020-02379-w>
- Terranova C, Doro L, Zancaner S, Zampini T, Mazzarolo C, Bonvicini B et al (2020) Criminological and medico-legal aspects in homicidal and suicidal sharp force fatalities. *J Forensic Sci* 65(4):1184–1190. <https://doi.org/10.1111/1556-4029.14285>
- Thoresen SO, Rognum TO (1986) Survival time and acting capability after fatal injury by sharp weapons. *Forensic Sci Int* 31(3):181–187. [https://doi.org/10.1016/0379-0738\(86\)90186-6](https://doi.org/10.1016/0379-0738(86)90186-6)
- Ventura F, Bonsignore A, Gallo M, Gallo M, Portunato F, De Stefano F (2010) A fatal case of suicidal stabbing and cutting. *J Forensic Leg Med* 17(3):120–122. <https://doi.org/10.1016/j.jflm.2009.12.006>
- Vrinceanu D, Banica B, Papacoccea R, Papacoccea T (2018) Self-inflicted laryngeal penetrating wounds with suicidal intention: two clinical cases. *Rom J Leg Med* 26:16–20. <https://doi.org/10.4323/rjlm.2018.16>
- Yadav A, Raheel MS, Kumar RL, Sharma SK, Kanwar H (2016) Cut-throat wounds: suicidal and homicidal-two case reports and review of literature. *Med Sci Law* 56(1):53–57. <https://doi.org/10.1177/0025802415591200>
- Zimmer G, Miltner E, Mattern R (1994) Zur Handlungsfähigkeit nach Stich- und Schnittverletzung [Capacity to act after stab and cutting injury]. *Arch Kriminol* 194(3–4):95–104 (German. PMID: 7811142)

## Publisher's Note

Springer Nature remains neutral with regard to jurisdictional claims in published maps and institutional affiliations.