

ORIGINAL ARTICLE

Open Access



# Age estimation by spheno-occipital synchondrosis fusion in South Indian population using computed tomography

Rajesh Nayak<sup>1</sup>, Nitika C. Panakkal<sup>2\*</sup>  and Visakh T<sup>3</sup>

## Abstract

**Background** Age estimation has paramount importance for the forensic practitioner. Depending on the timing of fusion, the spheno-occipital synchondrosis will be open during childhood and then later fuse during adulthood. Since there have been a lot of inconsistencies in terms of fusion degree, that can be attributed to variability in population or methodology. The aim of the present study was to determine the age of beginning of the spheno-occipital synchondrosis in the South Indian population using computed tomography.

**Results** The study reported a mean age of  $8.38 \pm 1.21$  for males and  $8.2 \pm 1.16$  for females in the stage 0 (completely open) category. Spheno-occipital synchondrosis began to fuse (stage 1) at the mean age of  $11.64 \pm 1.19$  for males and  $10.21 \pm 1.19$  for females.

**Conclusions** Spheno-occipital synchondrosis begins to close at the age of less than 15 years in males. Similarly, for females, the spheno-occipital synchondrosis begins to close at the age of less than 14 years. Also, a strong sexual dimorphism is seen as each stage of synchondrosis and starts earlier in females compared to males. In addition, the study also showed the degree of fusion increasing with age. This estimation will not only help in forensic and anthropological studies but also in assessing craniofacial growth in orthodontics.

**Keywords** Spheno-occipital synchondrosis, Age estimation, Computed tomography, South Indian population

## Background

Age estimation plays a crucial role in forensic and anthropological contexts. They help in estimating the age at death of bodies deteriorated, damaged or fragmentary (Ubelaker and Khosrowshahi 2019; Alkass et al. 2010). In living individuals, age estimation is required for logical affirmation of the judicial authority and certain

administrative departments (Pate et al. 2018). Estimation of age is more accurate for the immature skeletal system (Cardoso et al. 2014). Various skeletal markers, such as the root of the third molar tooth, the diaphysis-epiphysis fusion of the clavicle, tibia, calcaneus, occipital condyles, the fusion of skull sutures, cervical vertebrae and ossification of wrist joint have been studied for the age estimation (Cardoso et al. 2014; Hisham et al. 2018). Among these, the examination of skull sutures and ossification of the wrist joint may not always provide accurate results to estimate the age at the time of death (Can et al. 2014a; Akhlaghi et al. 2010). However, the degree of fusion of spheno-occipital synchondrosis (SOS) is considered to be a good indicator of age (Pate et al. 2018; Can et al. 2014a; Akhlaghi et al. 2010). The SOS is considered an active growth site that lengthens the skull base during the post-natal period (Yang et al. 2019; Ford 1958). The fusion of

\*Correspondence:

Nitika C. Panakkal

nitikacp@gmail.com; nitika.cp@manipal.edu

<sup>1</sup> Department of Radiodiagnosis, Kasturba Medical College, Manipal Academy of Higher Education, Mangalore, Karnataka, India

<sup>2</sup> Department of Medical Imaging Technology, Manipal College of Health Professions, Manipal Academy of Higher education, Karnataka, Manipal, India

<sup>3</sup> Department of Medical Imaging Technology, Manipal College of Health Professions, Manipal Academy of Higher Education, Manipal, Karnataka, India



© The Author(s) 2023. **Open Access** This article is licensed under a Creative Commons Attribution 4.0 International License, which permits use, sharing, adaptation, distribution and reproduction in any medium or format, as long as you give appropriate credit to the original author(s) and the source, provide a link to the Creative Commons licence, and indicate if changes were made. The images or other third party material in this article are included in the article's Creative Commons licence, unless indicated otherwise in a credit line to the material. If material is not included in the article's Creative Commons licence and your intended use is not permitted by statutory regulation or exceeds the permitted use, you will need to obtain permission directly from the copyright holder. To view a copy of this licence, visit <http://creativecommons.org/licenses/by/4.0/>.

the sphenoid and occipital bones proceeds from endocranial towards ectocranial, and the gap between the bones is completely closed in adulthood (Demirturk Kocasarac et al. 2016). Therefore, analysing the degree of fusion of the sphenoid-occipital synchondrosis will be useful for forensic age assessment due to its relatively late ossification (Sinanoglu et al. 2016; Krishan and Kanchan 2013). However, the literature reports a great amount of inconsistency in terms of fusion degree that can be ascribed to the variability in populations and various methodologies employed for examination (Sinanoglu et al. 2016; Shirley and Jantz 2011; Can et al. 2014b). The various methods include direct examination of skeletal material, dry skull, postmortem, bone histology, and imaging modalities. Although direct examination techniques are cost-effective, they are not always accurate. A synchondrosis may look completely closed in dry skull, however, it may not be so in the CT images of the skull (Bassed et al. 2010). Similarly, conventional radiography is also inexpensive and accessible, but there is a problem of superimposition and a lack of resolution that can interfere with the interpretation of the image. Therefore, imaging modalities like computed tomography that provide three-dimensional information have better resolution for visualising anatomical structures, thereby having a greater accuracy in analysing the various degrees of fusion of sphenoid-occipital synchondrosis (Sahni et al. 1998; Okamoto et al. 1996; Alhazmi et al. 2017). Therefore, this study aimed to assess the time of fusion of sphenoid-occipital synchondrosis for age estimations in the South Indian population using computed tomography.

## Methods

The study was conducted retrospectively in a tertiary care hospital in South India after approval from the Institutional Ethical Committee [IEC 547]. A total of 123 male

and 123 female participants, aged from 7 to 15 years, and having previously undergone a CT scan of the brain, PNS, temporal bone, cervical spine, orbits and facial bones were included in the study. The CT images that showed artefacts at the base of the skull were excluded from the study.

All the CT examinations were performed on a 128-slice Philips InCise CT and a 16-slice Big Bore CT scanner. Scans were performed using 120 kVp with automatic tube current modulation. The axial images of the CT scan were acquired in 1 mm, and all the images were reconstructed into coronal and sagittal sections.

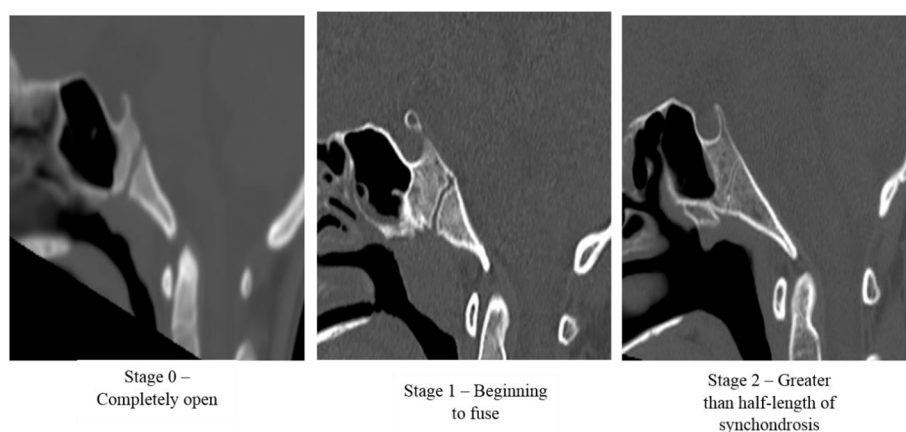
The images collected were retrieved from the PACS server, Mediff PACS (InstaRIS PACS version 4.1.0). The midsagittal section was considered the choice for viewing. The window level and window width of the obtained images were changed to 800 and 1600, respectively.

The fusion of SOS was assessed using a modified 3-stage system referred from Bassed et al. (Bassed et al. 2010). The stages are as follows, as shown in Fig. 1. Stage 0 indicates a completely open SOS. In stage 1, the SOS is beginning to close, starting with the fusion of the superior border. In stage 2, the synchondrosis is fused for more than half the length.

The images were assessed by two subject experts. In cases of disagreement between the observers, a third observer was asked to rescore the image.

## Statistical analysis

Descriptive statistics were used to find out the mean age and standard deviation for each stage. The homogeneity of variances was checked using the Levene test. As the age (in years) was positively skewed, a log transformation was used to be able to fit a two-way ANOVA model for analysis. Therefore, to evaluate the significant difference between the groups and biological sex among each



**Fig. 1** Stages of SOS fusion stages in the mid-sagittal plane

**Table 1** Age distribution of the sample population

Age	Male (N)	Female (N)	Total
7	14	14	28
8	18	24	42
9	8	9	17
10	6	18	24
11	16	23	39
12	14	17	31
13	15	9	24
14	17	7	24
15	15	2	17

group, a two-way ANOVA test was performed. For inter-observer agreement, Cohen’s Kappa test was performed. A Kappa value less than 0.20 indicated the poorest agreement. Value between 0.21 and 0.40 indicated slight agreement. Value between 0.41 and 0.60 and 0.61 and 0.80 indicated moderate and good agreement, respectively, and value above 0.81 indicated almost perfect agreement (Rosner 2011).

**Results**

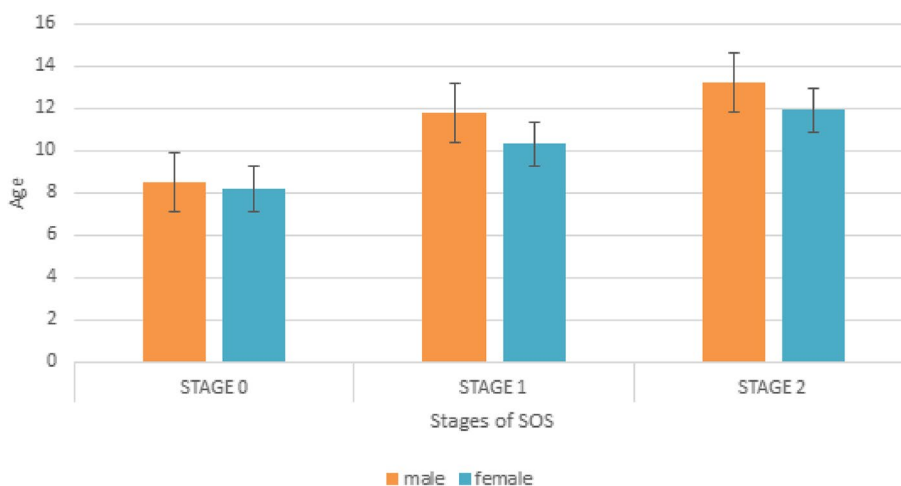
The study analysed the degree of SOS for 246 subjects ranging from 7 to 15 years. The distribution of the age sample is shown in Table 1.

**Inter-observer agreement**

The Kappa values showed almost perfect agreement ( $k=0.854$ ) between observer 1 and observer 2.

The study reported a mean age of  $8.38 \pm 1.21$  for males and  $8.2 \pm 1.16$  for females in the stage 0 (completely open) category. The speno-occipital synchondrosis began to fuse (stage 1) at the mean ages of  $11.64 \pm 1.19$  for males and  $10.21 \pm 1.19$  for females. With regards to semi-closed (stage 2), the mean age was found to be  $13.07 \pm 1.17$  and  $11.8 \pm 1.14$  for males and females, respectively (Fig. 2). The descriptive properties of various stages of both sexes are shown in Table 2.

According to the two-way ANOVA test, the study result showed a significant difference among various stages of SOS fusion with age ( $p < 0.001$ ). Similarly, the results also showed a significant difference among sex in all 3 categories ( $p < 0.001$ ). Therefore, the study depicted



**Fig. 2** Mean degree of fusion for each age group for males and females. Standard deviation is represented by error bars

**Table 2** Descriptive statistics for SOS in the study population

SOS stages	Gender	n	Mean	95% CI	SD	Min–Max age
Stage 0	M	41	8.38	7.95–8.65	1.21	7–14
	F	41	8.2	7.85–8.55	1.16	7–12
Stage 1	M	41	11.64	11.29–11.99	1.19	7–15
	F	41	10.21	9.86–10.56	1.19	7–14
Stage 2	M	41	13.07	12.72–13.42	1.17	9–15
	F	41	11.8	11.47–12.13	1.14	8–15

CI confidence interval, SD standard deviation, n number

that SOS closure occurs earlier in females (10.07) compared to males (11.03).

## Discussion

Age estimation has paramount importance for the forensic practitioner. Identifying the biological age of the individual depends on the skeletal indicator. The spheno-occipital synchondrosis is one such indicator that reflects the biological age. Information on the timing of spheno-occipital synchondrosis reported in literature shows that synchondrosis will be open during childhood and then later merge during adulthood (Ford 1958). A study conducted by Hariprasad et al. reported that there was no significant progression in SOS fusion after an age of 15 years in females and 16 years in males with a mean age of  $20.3 \pm 3$  and  $20 \pm 3.1$  in males and females, respectively among the South Indian population. However, this study only investigated the timing of complete closure of spheno-occipital synchondrosis (Nambiar et al. 2021). Hence, this study was conducted to assess the timing of beginning of the fusion of SOS. Based on the mean age of the study sample, we found that fusion starts at an age of  $11.64 \pm 1.19$  years for males and  $10.21 \pm 1.19$  years for females. These results were found to be similar to a study conducted by Salina Hisham et al., where the mean age at which SOS begins to fuse is 10.82 in females (Hisham

et al. 2018). However, for males, the SOS begins to fuse at a mean age of 13.74 years. Even though SOS status was assessed using CT, the study was conducted in a Malaysian population. Several studies report morphometric parameter differences among inter- and intra-populations (Pate et al. 2018; Bassed et al. 2010; Sharma et al. 2020). The common factors affecting inter- and intra-populations are geographical, biological, age-related, biological sex-related, ecological, and environmental aspects such as diet, climate and weather (Durtschi et al. 2009; Buretic-Tomljanovic et al. 2007).

The current study also shows a sexual dimorphism during the beginning of fusion, which is in accordance with various studies reported in literature (Pate et al. 2018; Hisham et al. 2018; Sinanoglu et al. 2016; Shirley and Jantz 2011; Can et al. 2014b; Okamoto et al. 1996). In the present study, the oldest male with an open SOS was 14 years old, whereas the oldest female with an open SOS was 12 years old. Table 3 demonstrates a summary of various studies reported in literature indicating the beginning of fusion for males and females in different populations.

As shown in the table, there is a variation in the time of fusion. These differences could be attributed to the differences in population. This highlights the requirement for a population specific data. The literature also

**Table 3** SOS fusion timing among genders found in literature in contrast with the current study showing the mode of assessment, sample size and place

Author	Publication year	Modalities for assessment	Gender	Sample size	Location	Age in year	
						Beginning of fusion	
						Male	Female
Ismail Ozgur Can (Can et al. 2014b)	2014	CT	Male	399	Germany	14	12.7
			Female	139			
Salina Hisham (Hisham et al. 2018)	2018	CT	Male	336	Malaysia	13.74	10.82
			Female	164			
Alper Sinanoglu (Sinanoglu et al. 2016)	2015	CBCT	Male	90	Turkey	13	12
			Female	148			
Husniye Demirturk Kocasarac (Demirturk Kocasarac et al. 2016)	2015	CBCT	Male	182	Turkey	11	12.3
			Female	167			
Anka Sharma (Sharma et al. 2020)	2020	CBCT	Male	145	Nagpur (India)	13	11
Female	126						
Oguzhan Ekizoglu (Ekizoglu et al. 2015)	2015	MRI	Male	455	Turkey	13.78	13.08
			Female	623			
Rajeshwar Sambhaji Pate (Pate et al. 2018)	2018	Cadavers	Male	117	Maharashtra (India)	14 - 15	11 - 12
			Female	81			
Natalie R. Shirley (Shirley and Jantz 2011)	2011	Direct inspection	Male	62	America	12.6 - 22.8	7.8 - 20.1
			Female	100			
Present study	2021	CT	Male	123	Karnataka (India)	11.64	10.21
			Female	123			

reports methodological differences that cause variation in the time of fusion. The most procedural variation depends on whether the research is conducted on live individuals or post-mortem. Several studies report a variation in results due to differences in assessment methods (Pate et al. 2018; Demirturk Kocasarac et al. 2016; Shirley and Jantz 2011; Okamoto et al. 1996). To analyse age, macroscopic and histological methods are used for post-mortem, whereas conventional radiography, CT, and MRI methods have been used for live individuals (Pate et al. 2018; Demirturk Kocasarac et al. 2016; Shirley and Jantz 2011; Okamoto et al. 1996; Ekizoglu et al. 2015). It is shown that a macroscopic assessment of SOS generally overestimates the age. On the other hand, various studies have reported the advantages of CT scans over conventional radiographs and macroscopic techniques. Due to its superior image quality in terms of resolution, obtaining three-dimensional images, and enabling earlier detection and accurate interpretation, CT can be used effectively to demonstrate various stages of speno-occipital synchondrosis (Shirley and Jantz 2011; Bassed et al. 2010; Okamoto et al. 1996; Sharma et al. 2020). However, cost, radiation exposure, and accessibility are a few limitations of CT scans (Demirturk Kocasarac et al. 2016). The variability in SOS among different populations and studies can also be attributed to maturational events. A study conducted by Alhazmi A et al. reported a significant relation between the onset of puberty and SOS closure. The systemic and hormonal changes in a growing adolescent can be the reason affecting the closure (Alhazmi et al. 2017). However, the present study did not take into account the onset of puberty and its relationship to SOS closure. Also, as the current study collected the data retrospectively, it did not take into account the socio-economic status or ethnicity background, therefore, further studies can be done to understand the relationship of SOS closure with respect to these factors as well. Another limitation was that the study had a limited sample size. Therefore, studies involving a larger sample can be done to represent a diverse population. Also, there is a high chance that the fusion of SOS can vary among the South and North Indian populations due to morphometric differences caused by ecological and environmental factors such as climate and diet. Therefore, studies can be conducted in this region to provide a unique perception of the variability in population throughout the country.

## Conclusions

The study concluded that in the South Indian population, when the SOS begins to close, the age is less than 15 years in males. Similarly, for females, if SOS begins

to close, the age is less than 14 years. Also, a strong sexual dimorphism is seen as each stage of synchondrosis starts earlier in females compared to males. This estimation will not only help in forensic and anthropological studies but also in assessing craniofacial growth in orthodontics.

## Abbreviations

SOS	Spheno-occipital synchondrosis
CT	Computed tomography
PNS	Paranasal sinuses
kVp	Kilovoltage potential
PACS	Picture Archival communication system
ANOVA	Analysis of variance
MRI	Magnetic resonance imaging

## Acknowledgements

The authors would like to acknowledge, Kasturba Hospital and Manipal College of Health Professions for their support to undertake this study. We also extend our heartfelt gratitude to the faculties and Head of the Department of Radio-diagnosis and Imaging for their cooperation in the phantom study. We also acknowledge the support of the Department of Statistics for the guidance during data analysis and interpretation.

## Authors' contributions

NCP conceptualised the study. VT has given inputs in the study design. RN collected the data. NCP and VT analysed the data. RN wrote the final draft of the manuscript. NCP and VT revised and added inputs to the manuscripts.

## Funding

There is no external funding for this research project as this project was conducted within the institute itself which provided us with all facilities required to conduct the project.

## Availability of datamaterials

Since the data sets in the study are derived from DICOM images, the images cannot be shared publicly to maintain participant confidentiality. However, the data derived from those images are well summarized in the article and can be made available from the corresponding author on reasonable request.

## Declarations

### Ethics approval and consent to participate

The study was approved by the institute ethical committee and followed all ethical guidelines during the research.

### Consent for publication

Not applicable.

### Competing interests

The authors declare that they have no competing interests.

Received: 26 January 2023 Accepted: 28 May 2023

Published online: 06 June 2023

## References

- Akhlaghi M, Taghaddosinejad F, Sheikhezadi A, Valizadeh B, Shojaei SM (2010) Age-at-death estimation based on the macroscopic examination of speno-occipital sutures. *J Forensic Leg Med* 17(6):304–308. <https://doi.org/10.1016/j.jflm.2010.04.009>
- Alhazmi A, Vargas E, Palomo JM, Hans M, Latimer B, Simpson S (2017) Timing and rate of speno-occipital synchondrosis closure and its relationship



- to puberty. *PLoS One* 12(8):1–16. <https://doi.org/10.1371/journal.pone.0183305>
- Alkass K, Buchholz BA, Ohtani S, Yamamoto T, Druid H, Spalding KL (2010) Age estimation in forensic sciences: application of combined aspartic acid racemization and radiocarbon analysis. *Mol Cell Proteomics* 9(5):1022–1030. <https://doi.org/10.1074/mcp.M900525-MCP200>. Epub 2009 Dec 4. PMID: 19965905; PMCID: PMC2871409
- Bassed RB, Briggs C, Drummer OH (2010) Analysis of time of closure of the spheno-occipital synchondrosis using computed tomography. *Forensic Sci Int* 200(1–3):161–164. <https://doi.org/10.1016/j.forsciint.2010.04.009>
- Buretic-Tomljanovic A, Giacometti J, Ostojic S, Kapovic M (2007) Sex-specific differences of craniofacial traits in Croatia: the impact of environment in a small geographic area. *Ann Hum Biol* 34(3):296–314. <https://doi.org/10.1080/03014460701211017>
- Can IO, Ekizoglu O, Hocaoglu E, Inci E, Sayin I, Kaya KH (2014a) Forensic age estimation by spheno-occipital synchondrosis fusion degree: computed tomography analysis. *J Craniofac Surg* 25(4):1212–1216. <https://doi.org/10.1097/scs.0000000000000847>
- Can IO, Ekizoglu O, Hocaoglu E (2014b) Forensic age estimation by spheno-occipital synchondrosis fusion degree: computed tomography analysis. *Journal of Craniofacial Surgery* 24(4):1212–1216. <https://doi.org/10.1097/scs.0000000000000847>
- Cardoso HFV, Abrantes J, Humphrey LT (2014) Age estimation of immature human skeletal remains from the diaphyseal length of the long bones in the postnatal period. *Int J Legal Med* 128(5):809–824. <https://doi.org/10.1007/s00414-013-0925-5>
- Demirturk Kocasarac H, Sinanoglu A, Noujeim M, Helvacioğlu Yigit D, Baydemir C (2016) Radiologic assessment of third molar tooth and spheno-occipital synchondrosis for age estimation: a multiple regression analysis study. *Int J Legal Med* 130(3):799–808. <https://doi.org/10.1007/s00414-015-1298-8>
- Durtschi RB, Chung D, Gentry LR, Vorperian HK (2009) Developmental craniofacial anthropometry: assessment of race effects. *Clinic Anat* 22(7):800–808. <https://doi.org/10.1002/ca.20852>
- Ekizoglu O, Hocaoglu E, Can IO, Inci E, Aksoy S (2015) Spheno-occipital synchondrosis fusion degree as a method to estimate age: a preliminary, magnetic resonance imaging study. *Aust J Forensic Sci* 48(2):159–170. <https://doi.org/10.1080/00450618.2015.1042047>
- Ford HER (1958) Growth of the human cranial base. *Am J Orthod* 44:498–506. [https://doi.org/10.1016/0002-9416\(58\)90082-4](https://doi.org/10.1016/0002-9416(58)90082-4)
- Hisham S, Flavel A, Abdullah N, Noor MHM, Franklin D (2018) Quantification of spheno-occipital synchondrosis fusion in a contemporary Malaysian population. *Forensic Sci Int* 284(2018):78–84. <https://doi.org/10.1016/j.forsciint.2017.12.046>
- Krishan K, Kanchan T (2013) Evaluation of spheno-occipital synchondrosis: a review of literature and considerations from forensic anthropologic point of view. *J Forensic Dent Sci* 5(2):72
- Nambiar HT, Mehanaz A, Panakkal NC, Suresh S, Visakh T (2021) A Prospective study to determine the timing of complete fusion of spheno-occipital synchondrosis using computed tomography. *Indian J Forensic Med Toxicol* 15(4):1284–1289. <https://doi.org/10.37506/ijfimt.v15i4.16886>
- Okamoto K, Ito J, Tokiguchi S, Furusawa T (1996) High-resolution CT findings in the development of the sphenooccipital synchondrosis. *Am J Neuro-radiol* 17(1):117–120. Available from: <http://www.ncbi.nlm.nih.gov/pmc/articles/PMC8337967/>
- Pate RS, Tingne CV, Dixit PG (2018) Age determination by spheno-occipital synchondrosis fusion in Central Indian population. *J Forensic Leg Med* 54:39–43. <https://doi.org/10.1016/j.jflm.2017.12.013>
- Rosner B (2011) *Fundamentals of Biostatistics*, 7th edn. Brooks/Cole, Cengage Learning, Boston
- Sahni D, Jit I, Neelam SS (1998) Time of fusion of the basisphenoid with the basilar part of the occipital bone in northwest Indian subjects. *Forensic Sci Int* 98(1–2):41–45. [https://doi.org/10.1016/s0379-0738\(98\)00135-2](https://doi.org/10.1016/s0379-0738(98)00135-2)
- Sharma A, Kumbhare SP, Kalaskar AR, Motghare P, Gondivkar S, Upmanyu A (2020) Age estimation in an Indian subpopulation by cone-beam computed tomographic analysis of spheno-occipital synchondrosis fusion. *Forensic Sci Int Rep* 2(February):100085. <https://doi.org/10.1016/j.fsr.2020.100085>
- Shirley NR, Jantz RL (2011) Spheno-occipital synchondrosis fusion in modern Americans. *J Forensic Sci* 56(3):580–585. <https://doi.org/10.1111/j.1556-4029.2011.01705.x>
- Sinanoglu A, Kocasarac HD, Noujeim M (2016) Age estimation by an analysis of spheno-occipital synchondrosis using cone-beam computed tomography. *Leg Med* 18:13–19. <https://doi.org/10.1016/j.legalmed.2015.11.004>
- Ubelaker DH, Khosrowshahi H (2019) Estimation of age in forensic anthropology: historical perspective and recent methodological advances. *Forensic Sci Res* 4(1):1–9. <https://doi.org/10.1080/20961790.2018.1549711>. PMID: 30915413; PMCID: PMC6427487
- Yang JH, Cha BK, Choi DS, Park JH, Jang I (2019) Time and pattern of the fusion of the spheno-occipital synchondrosis in patients with skeletal Class I and Class III malocclusion. *Angle Orthod* 89(3):470–479. <https://doi.org/10.2319/052218-386.1>

## Publisher's Note

Springer Nature remains neutral with regard to jurisdictional claims in published maps and institutional affiliations.

Submit your manuscript to a SpringerOpen® journal and benefit from:

- Convenient online submission
- Rigorous peer review
- Open access: articles freely available online
- High visibility within the field
- Retaining the copyright to your article

Submit your next manuscript at ► [springeropen.com](https://www.springeropen.com)