

ORIGINAL ARTICLE

Open Access



# Traumatic asphyxia in the young: report of two cases and literature review

Abdulsalam Y. Taha\*

## Abstract

**Background:** Traumatic asphyxia, also called masque ecchymotique, Ollivier's syndrome, and Perthes syndrome, is a rare but serious form of chest trauma described for the first time by Ollivier in 1837. The purpose of this study is to report our experience with two cases of traumatic asphyxia and discuss their management in view of the relevant literature.

**Results:** During a 6-year period, the author treated 2 cases of traumatic (crush) asphyxia in a local teaching hospital. The two patients were males, aged 20 and 30 years and were crushed beneath their vehicles. The presenting symptoms and signs were irritability, dyspnea, cervicofacial cyanosis, petechiae, and sub-conjunctival hemorrhages. The second patient suffered multiple rib fractures, hemopneumothorax, pulmonary contusion, vertebral fracture, and paraplegia. Negative surgical exploration for suspected cardiac tamponade was performed in the first case, while the second was managed conservatively.

The first patient survived whereas the second succumbed because of the associated injuries.

**Conclusions:** Due to its widespread lesions, traumatic asphyxia should be looked upon as a systemic syndrome. Timely accurate diagnosis and supportive treatment save the majority of patients with traumatic asphyxia. In this rare syndrome, death may result from asphyxia secondary to thoracic compression or from the associated injuries.

**Keywords:** Traumatic asphyxia, Ollivier's syndrome, Perthes syndrome, Masque ecchymotique

## Background

Traumatic asphyxia (TA) is a rare yet serious clinical syndrome described for the first time by Ollivier, who performed an autopsy of 23 patients crushed to death in mob violence in 1837. Perthes in 1898 gave the first complete description of the clinical picture (Reichert and Martin 1951; Kamali et al. 2013; Shiber et al. 2013; Cortis et al. 2015; Gulbahar et al. 2015; Lateef 2015). Different scenarios of blunt trauma to the chest and/or upper abdomen (Byard et al. 2003; Miyaishi et al. 2004; Domènech et al. 2012; Cappelletti et al. 2019) associated with the "fear response" and Valsalva maneuver (Lee

et al. 1991; Miyaishi et al. 2004; Eken and Yigit 2009; Ser-taridou et al. 2012; Shiber et al. 2013; Cortis et al. 2015) results in sudden increase in intra-thoracic pressure and hence displacement of venous blood through the valve-less superior vena cava (SVC) leading to dilatation and possible rupture of venules and capillaries (Conwell 1927; Reichert and Martin 1951; Choi et al. 2010; Sertaridou et al. 2012; Gulbahar et al. 2015). The characteristic signs and symptoms of the syndrome include edema, violet to blue discoloration of the face, neck, variable portions of the upper trunk, and occasionally the arms besides sub-conjunctival hemorrhage. Neurological and other systemic manifestations may be present as well (Conwell 1927; El Koraichi et al. 2012; Cortis et al. 2015; Lateef 2015). The discoloration usually subsides within days, while sub-conjunctival hemorrhage may persist for weeks (Shiber et al. 2013; Lateef 2015). The reason why the signs of traumatic asphyxia are confined to the head and upper

\*Correspondence: [abdulsalam.taha@univsul.edu.iq](mailto:abdulsalam.taha@univsul.edu.iq)

Department of Thoracic and Cardiovascular Surgery, College of Medicine, University of Sulaimani, Mamostayan Street 112, Road 33, House 5, Sulaimaniyah, Region of Kurdistan 46001, Iraq

chest seems to be unrelated to venous valves protecting the lower part of the body as suggested by Lateef (Lateef 2015). Tucker and Burns (Tucker and Burns 2021) discussed the anatomy of the inferior vena cava (IVC) in detail and confirm that it has no valves. Furthermore, Marcus et al. (Marcus et al. 2019) confirm that the pathophysiological backflow in pulmonary hypertension is similar in both the superior and inferior vena cava, which would not be the case if one had valves and the other did not. Physicians who are clinically aware of TA should face no difficulty in making the correct diagnosis. However, in the absence of the typical clinical features in subjects who die at the site of the accident, the diagnosis of TA can sometimes be one of exclusion (Byard et al. 2006). The treatment is generally supportive although certain associated injuries may require surgery (Eken and Yigit 2009; Lateef 2015). Despite the alarming appearance of patients with TA, the majority have a favorable prognosis (Shiber et al. 2013; Lateef 2015). In this rare syndrome, death may result from asphyxia secondary to thoracic compression or from the associated injuries (Byard et al. 2006).

Herein, 2 cases of traumatic asphyxia in young patients treated by the author in 6-year period in a local teaching hospital are reported. The diagnosis, treatment, and prognosis of this rare yet serious syndrome are discussed by reviewing the relevant literature.

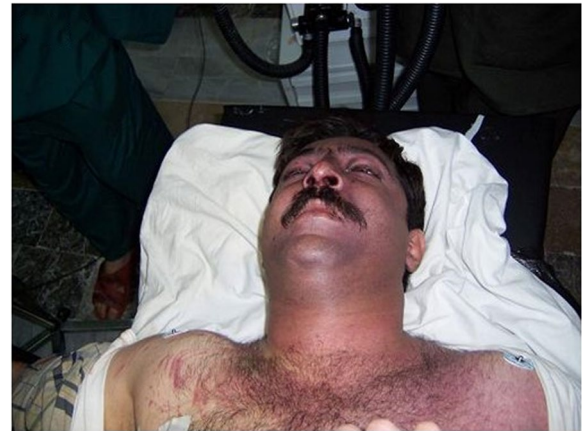## Methods

Clinical evaluation and detailed management of two cases of traumatic asphyxia managed by the author over a period of 6 years (2004–2010) in a local teaching hospital are described herein.

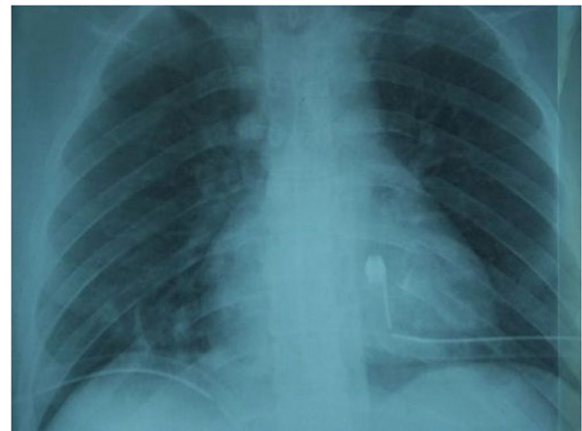
## Results

### Case 1

A man of 30 was admitted to the Emergency Department on March 19, 2004, with severe shortness of breath (SOB) and irritability following thoracic compression for undetermined period by a heavy vehicle (Fig. 1). He was pinned to the ground by his car while repairing it. The resident doctor placed bilateral chest tubes on clinical suspicion of hemo-/pneumothorax, but nothing was drained. On exam, the patient was breathless and irritable with bluish to violet cyanotic discoloration of face, neck, and upper chest besides bilateral sub-conjunctival hemorrhages. The neck was edematous, air entry to both sides of the chest was good, but heart sounds were distant. Chest X-ray (CXR) (Fig. 2) revealed a normal-sized heart with fully expanded lungs and 2 chest tubes. The electrocardiogram (ECG) (Fig. 3) showed sinus tachycardia and normal voltage, but echocardiography could not be arranged. Urgent surgical exploration via median sternotomy revealed no evidence of cardiac tamponade



**Fig. 1** Bluish to violet cyanotic discoloration of the face, neck, and upper chest in case 1

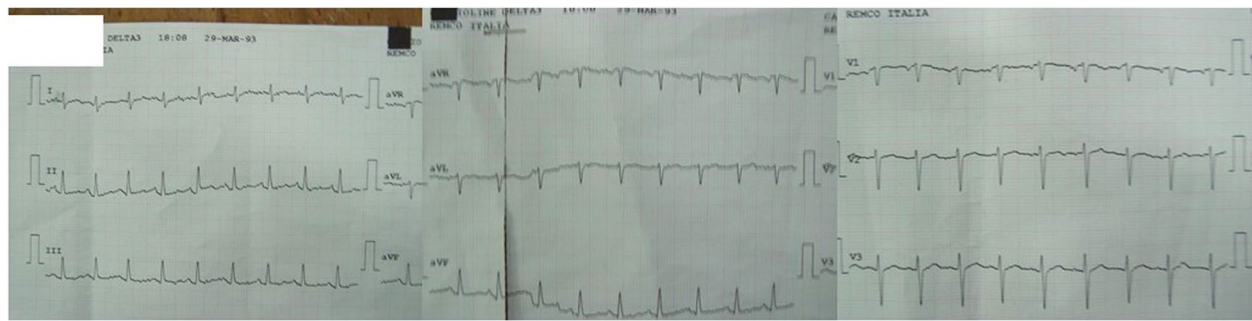


**Fig. 2** Chest X-ray of case 1 shortly following admission showing fully expanded lungs, bilateral chest tubes, and normal-sized heart

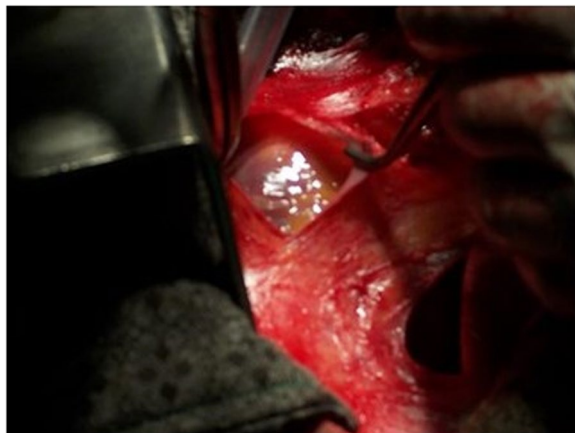
(Fig. 4). Supportive measures including pain killers, antibiotics, and oxygen were continued. The patient gradually improved. Respiration became quiet and discoloration faded (Fig. 5 and Fig. 6). He was then discharged home after several days in a very good state.

### Case 2

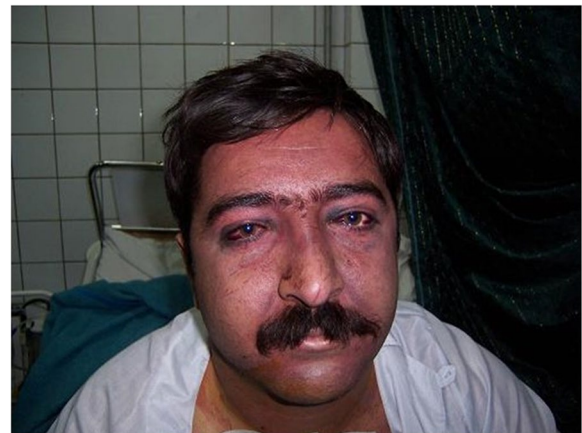
A 20-year-old man admitted to the Emergency Department on January 8, 2010, with severe SOB, irritability, and inability to move the lower limbs. The patient sustained 30-minutes severe thoracic compression by his heavy vehicle after slipping of the supporting hydraulic jack. On exam, there was a bluish to violet cyanotic cervicofacial discoloration and sub-conjunctival hemorrhages. The neck and face were edematous. The pulse



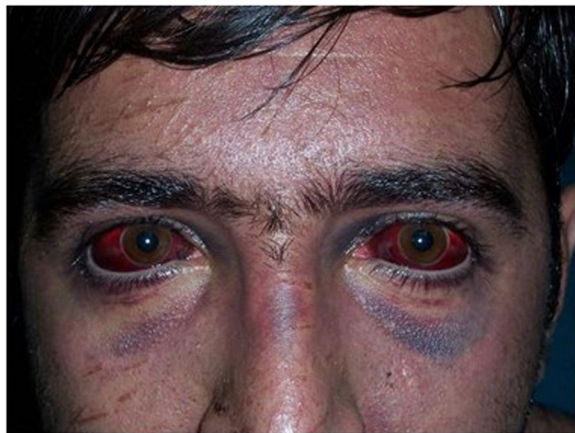**Fig. 3** ECG in case 1 with sinus tachycardia and normal voltage



**Fig. 4** No evidence of cardiac tamponade on exploration



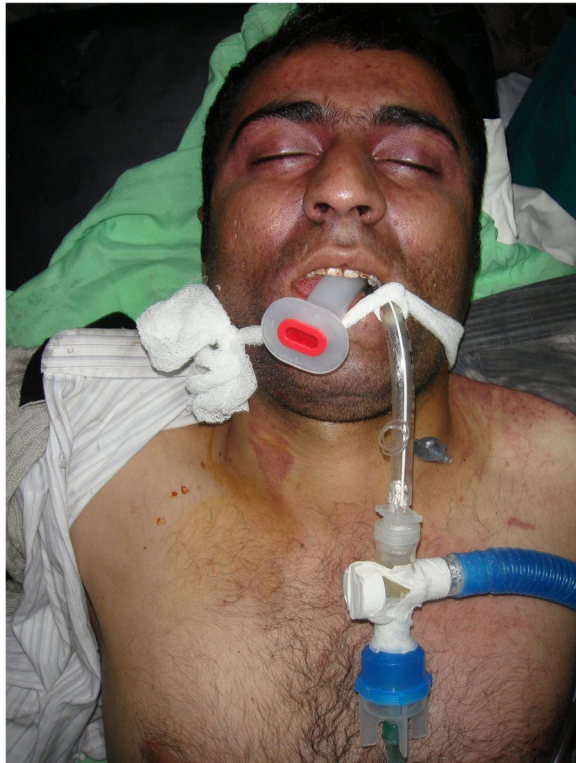**Fig. 6** More resolution of sub-conjunctival hemorrhage and facial discoloration few days after trauma



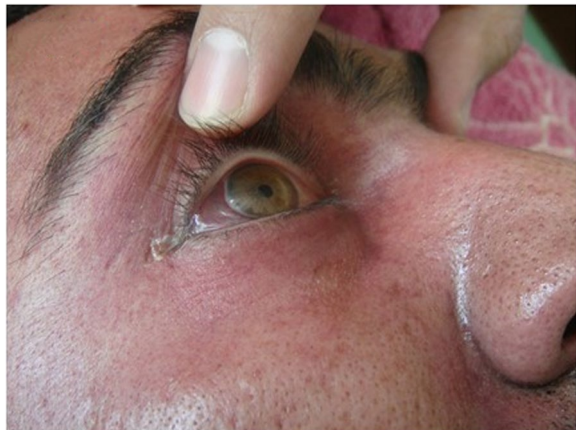**Fig. 5** Sub-conjunctival hemorrhage and facial blue discoloration starting to fade

was rapid and blood pressure (BP) was low. There was no deformity of sternum and no paradoxical chest wall movement, but air entry to the right chest was

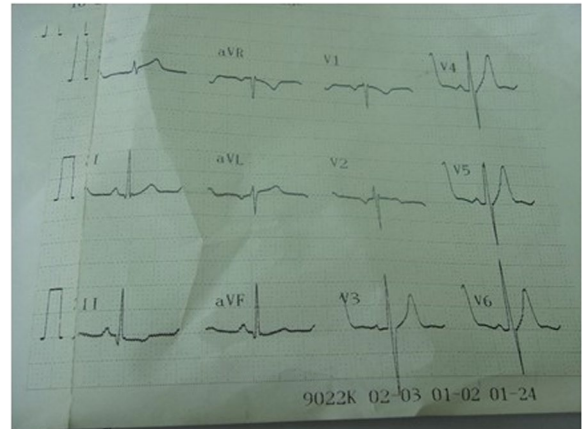
reduced. A diagnosis of traumatic asphyxia with paraplegia was made. An endotracheal tube was immediately placed (Fig. 7 and Fig. 8), and propofol IV infusion was started for sedation. ECG (Fig. 9) and echocardiography were normal with no evidence of hemopericardium. Chest X-ray (Fig. 10) and CT scan of the chest (Fig. 11) revealed right-sided hemopneumothorax, surgical emphysema, and multiple rib fractures. Spine CT scan (Fig. 12) revealed fracture/dislocation of D12-L1 vertebrae. Brain CT scan (Fig. 13) showed brain edema. Right-sided tube thoracostomy drained 1000 ml blood. Antibiotics and steroids (IV dexamethasone 8 mg tds) were given. On the 2nd day, there was an improvement in the hemodynamic as well as respiratory status of the patient as BP raised to 130/65 mmHg and oxygen saturation improved. Unfortunately, this improvement was not maintained, and the patient began to deteriorate. Mechanical respiration was needed on the 3rd day, and unfortunately, death occurred on the 4th day mostly because of respiratory insufficiency.



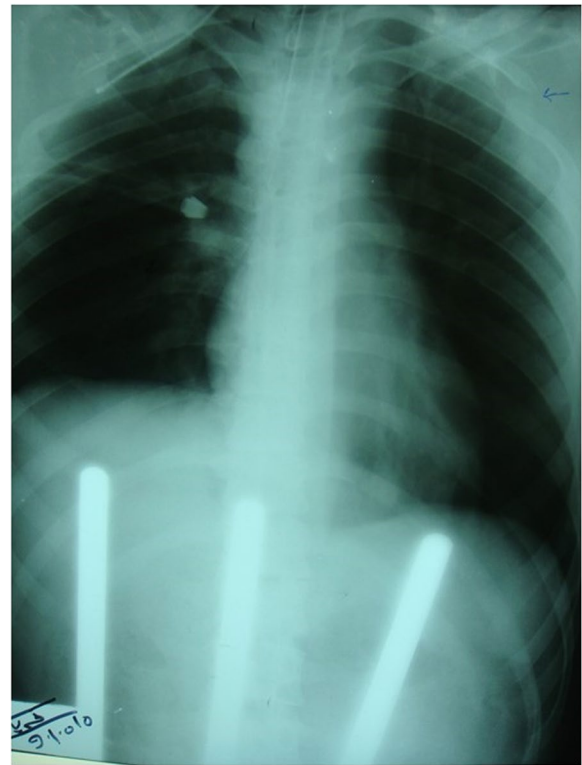
**Fig. 7** Bluish to violet cyanotic discoloration of face and neck of sedated and intubated 2nd patient in the series



**Fig. 8** A close view of case 2 showing the discoloration of the face and sub-conjunctival hemorrhage



**Fig. 9** Basically normal ECG in case 2



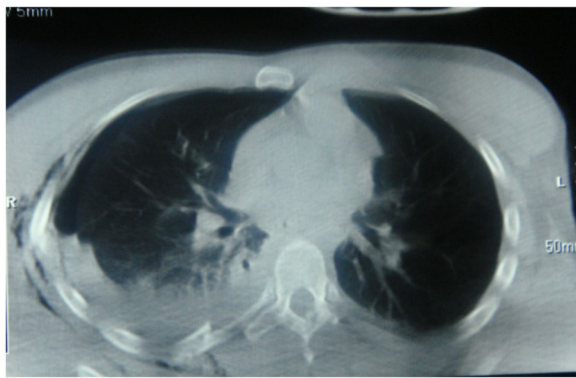**Fig. 10** Chest X-ray of the 2nd patient showing rib fracture and right-side chest tube for hemopneumothorax

## Discussion

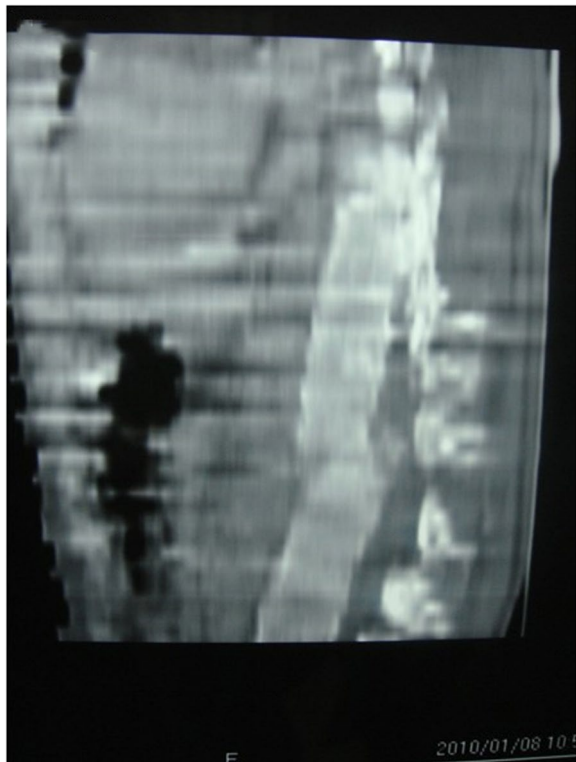
### The index cases

During a 6-year period, the author of this paper encountered 2 patients with TA. The small number of patients reflects the rarity of the syndrome. In fact, the first case

was misdiagnosed as cardiac tamponade and unfortunately underwent exploratory median sternotomy which proved to be negative. This surgical exploration was unnecessary as the patient had typical history of thoracoabdominal compression by his vehicle while repairing it followed by edema and blue discoloration of the face,



**Fig. 11** CT scan of the chest in case 2 showing right-side hemopneumothorax, rib fractures, and surgical emphysema



**Fig. 12** Spine CT scan in case 2 showing vertebral fracture

neck, and upper chest. He was restless and agitated due to cerebral hypoxia. The resident doctor introduced chest tubes to both sides of the chest anticipating hemo-/pneumothorax, but no blood or air collection was drained. Clinical awareness on the side of the physician would have saved the patient surgery. Fortunately, and despite the trauma of surgery, the patient had a smooth recovery with gradual subsidence of signs and symptoms of TA.

He went home several days after the trauma in excellent condition and gave us a valuable lesson and unforgettable experience.

The situation was quite different with the 2nd case which was received almost 6 years later. The clinical diagnosis of TA could be easily made in this patient who sustained traumatic insults followed by the development of typical edema, cervicofacial blue discoloration, and sub-conjunctival hemorrhage. The patient unfortunately expired on the 4th day. He had multiple injuries including rib fracture, hemopneumothorax, pulmonary contusion, and concomitant paraplegia due to vertebral fracture at D12/L1 level. Despite intensive care, closed tube thoracostomy, and mechanical ventilation, the patient ultimately died most probably because of cerebral anoxia.

#### Definition, nomenclature and incidence

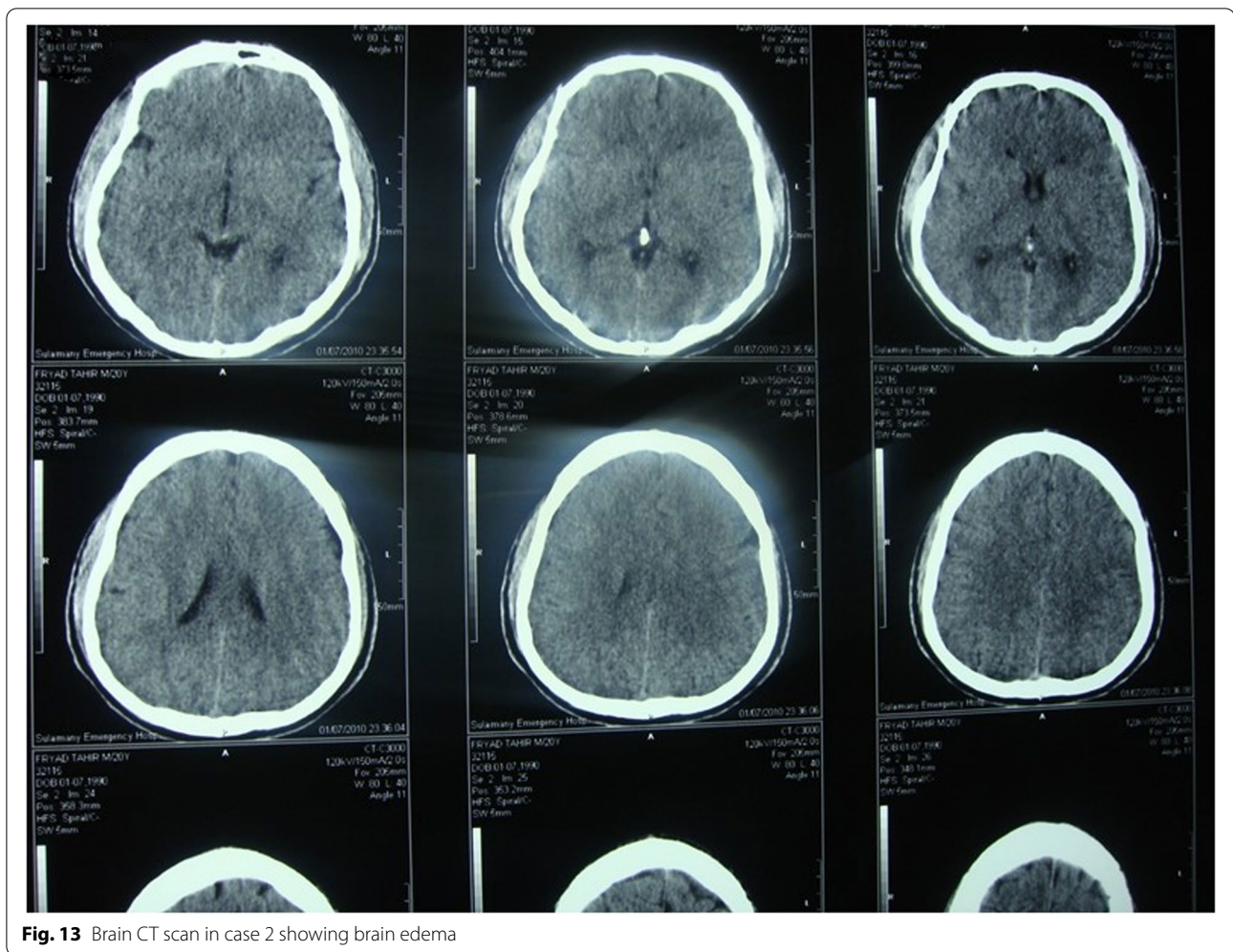
Asphyxia (from the Greek words a “without” and sphysis, “heartbeat”) is a condition of deficient tissue oxygenation leading to hypoxia with different etiologies. Traumatic asphyxia is a mechanical cause of hypoxia resulting from external compression and blunt thoracic trauma (Lateef 2015). Traumatic asphyxia has other names such as crush asphyxia (Sertaridou et al. 2012; Lateef 2015), Ollivier’s syndrome (Sertaridou et al. 2012; Gulbahar et al. 2015), Perthes syndrome (Sertaridou et al. 2012; Gulbahar et al. 2015), and “ecchymotic mask” (Gulbahar et al. 2015). The incidence of traumatic asphyxia in adults is reported to be one case in every 18,500 accidents. The incidence in children is not known; however, it can be assumed to be low because of the greater elasticity of children’s rib cages. Byard and co-workers encountered only six cases of TA among boys aged 2–15 years during a period of 34 years (Cortis et al. 2015).

#### History

Traumatic asphyxia was first observed by Charles-Prosper Ollivier d’Angers (1796–1845). Ollivier termed the syndrome “masque ecchymotique” when noted the characteristic features in patients trampled to death by crowds in Paris in 1837. It was not until 1898 that Perthes made a more extensive review and detailed its pathophysiology and features including mental dullness, hyperpyrexia, hemoptysis, tachypnea, and “contusion pneumonia” (Reichert and Martin 1951; Karamustafaoglu et al. 2010; Kamali et al. 2013; Cortis et al. 2015; Lateef 2015).

#### The trauma scenarios

Fatal TA is most often reported in adults or older children, when an individual is trapped under a motor vehicle (Byard et al. 2003; Lateef 2015) or pinned to a wall by a car while repairing it (Miyaiishi et al. 2004) or buried



**Fig. 13** Brain CT scan in case 2 showing brain edema

in sand or soil with the mouth and nose exposed (Byard et al. 2003; Miyaiishi et al. 2004; Cortis et al. 2015). Motorcycle accidents account for many cases as well (Kamali et al. 2013; Cortis et al. 2015; Lateef 2015) Other causes include heavy machines/furniture crashes (Kamali et al. 2013; Lateef 2015) or falling in a narrow space (Lateef 2015). Cappelletti et al. described a case of a woman who died from a combined traumatic and confined space asphyxia, after being trapped under some of the objects amassed in her apartment (Cappelletti et al. 2019). Gulbahar et al. described the case of a male 32 years old who developed TA due to fall of an elevator cabin on him (Gulbahar et al. 2015).

Traumatic asphyxia may occur during incidents of mass panic. Gill et al. reported nine fatal accidents at a community basketball game in New York City in 1991. Further case reports in 2003 referred to 21 fatalities in a nightclub in Chicago (Cortis et al. 2015). During a human rush at a fireworks display in Japan in 2001, eleven people were killed and 247 were injured

(Motomura et al. 2019). The 2010 Love Parade accident in Germany resulted in the deaths of 21 people. In 2010, 347 people were killed at the Khmer Water Festival in Cambodia. Crowd accidents during the Hajj, the annual Islamic pilgrimage to Mecca, result in deaths every few years: 1426 in 1990, 270 in 1994, 119 in 1998, 35 in 2001, 14 in 2003, 251 in 2004, and 380 in 2006 (Motomura et al. 2019).

Traumatic asphyxia has also been described in persons struggling violently to resist arrest by police (Cortis et al. 2015). Miyaiishi et al. presented an unusual case of negligent homicide by thorax compression. The 58-year-old man was restrained in the prone position by six prison officers. They were ordered by their 3 superiors to continue restraining the victim for about 15 min until he died (Miyaiishi et al. 2004). Rare causes of TA include automatic revolving doors accidents (Cortis et al. 2015), deep-sea diving, epileptic seizures, difficult delivery, and asthmatic attacks (Kamali et al. 2013; Lateef 2015). Domenech et al. reported a very rare case of TA in a

middle-aged man who was killed by the folding bunk bed in a hotel (Domènech et al. 2012).

### Pathophysiology

It is generally considered that a compressive force to the thoracoabdominal region together with the “fear response” (deep breath and closing of the glottis) (Landercaasper and Cogbill 1985; Lee et al. 1991; Eken and Yigit 2009; Cortis et al. 2015) causes a huge increase in the central venous pressure. This induces reversal of venous blood flow from the heart through the SVC into the innominate and jugular veins of the head and neck. The back transmission of the elevated central venous pressure to the head and neck venules and capillaries, while arterial flow is continued, results into capillary stasis and rupture, producing the characteristic upper body petechial and sub-conjunctival hemorrhages. The lack of petechiae in the lower body may be due to the compressive obstruction of the IVC in the chest or abdomen. Furthermore, the fact that the lower part of the body is protected from back transmission of venous pressure by a series of valves could be another mechanism, since the SVC, innominate, and jugular veins have no valves (Conwell 1927; Reichert and Martin 1951; Miyashita et al. 2004; Sertaridou et al. 2012; Kamali et al. 2013; Shiber et al. 2013; Cortis et al. 2015; Gulbahar et al. 2015; Lateef 2015). Crush asphyxia may follow prolonged or a very short duration compression, although the literature reports an average period of 2–5 min (Kamali et al. 2013).

Experimentally, by means of intrathoracic occlusion of the SVC, sustained discoloration of the head and neck and mucous membranes, with retinal hemorrhages, have been obtained, which persisted for days and resembled in effect traumatic asphyxia as observed clinically (Reichert and Martin 1951). Beach and Cobb examined sections of the skin microscopically and conclusively showed that there was no extravasation of blood outside the vessels but just distension (Conwell 1927; Reichert and Martin 1951). However, Choi et al. believe that excessive pressure may cause an actual extravasation of erythrocytes from the vessels in the conjunctival and buccal mucosa whose tissue does not support the vessels (Choi et al. 2010).

The condition is characterized by a marked discoloration immediately following the injury, which usually involves the head, neck, and face down to the clavicle in front and posteriorly along the back and shoulders at the level of the lower border of the trapezius muscle (Conwell 1927). Moreover, the characteristic signs include facial and upper chest petechiae and sub-conjunctival hemorrhages. Neurological signs due to cerebral edema and temporary loss of vision as a result of retinal edema have been frequently reported (Lateef 2015). The extent of the

signs and symptoms depend on the duration and severity of the compression that the thorax and upper abdomen are exposed to (Gulbahar et al. 2015). Cervicofacial cyanosis is found in 95%, cervicofacial petechiae in 84%, and sub-conjunctival hemorrhage in 91% of cases described (Cortis et al. 2015). Superior vena cava obstruction and basilar skull fracture have features that closely resemble the appearance of traumatic asphyxia and should be ruled out (Sertaridou et al. 2012).

### Traumatic asphyxia is a systemic syndrome

Due to diversity and widespread lesions produced by TA, many authors consider it a systemic syndrome. Thoracic, cerebral, ophthalmic, auditory, spinal, and peripheral nerve lesions are some examples.

### Thoracoabdominal and cardiac injuries

Pulmonary contusion, hemo-/pneumothorax, and flail chest are the most common injuries accompanying Perthes syndrome (Kamali et al. 2013; Gulbahar et al. 2015). Signs of pulmonary injury like dyspnea, tachypnea, and hemoptysis may be observed (Gulbahar et al. 2015). Lateef H described the case of a 39-year-old male who developed TA after severe blunt chest trauma during his work at a construction site. The patient had multiple injuries to the chest, abdomen, head, and neck, which were treated conservatively. An associated diaphragmatic injury was successfully treated by video-assisted thoracoscopic surgery (Lateef 2015). An increase in the abdominal pressure may lead to organ injury, hematemesis, and hematuria (Gulbahar et al. 2015). In contrast, cardiac injuries during TA are extremely rare. Only two cases of cardiac contusion and one of ventricular rupture have been reported so far. A normal ECG does not rule out blunt cardiac injury. A rare consequence of TA is delayed myocardial infarction due to coronary artery contusion (Sertaridou et al. 2012; Gulbahar et al. 2015).

### Cerebral manifestations

Reports have postulated that the pathogenesis of neurologic manifestations is related to ischemia of the brain or spinal cord secondary to venous obstruction and elevated pressures (Westphal et al. 2013). According to Perthes, neurological injury in TA includes cerebral hypoxia or anoxia, ischemia, venous hypertension, cerebral vascular congestion, rupture of small vessels, petechial hemorrhages, and hydrostatic edema. CT scans of the brain are usually normal, whereas in fatal cases, autopsy shows only petechiae and congestion, suggesting brain injury at the cellular level. Neurologic manifestations of the syndrome include loss of consciousness, prolonged but self-limiting confusion, disorientation, agitation, restlessness, and seizures (Sertaridou et al. 2012). Both cases reported

herein were restless and agitated. The CT scan of the brain in the 2nd case was normal.

### **Spinal cord lesions**

Paraparesis and paraplegia may accompany TA either because of an associated vertebral fracture with spinal cord compression (like our 2nd case) or without radiological abnormality. Heuer (1923) reported paraparesis in one case of TA (Despard 1909; Leech and Cuthbert 1972). Likewise, Reichert and Martin (1951) reported paraplegia concomitant with TA in a 4-year old girl in whom laminectomy showed no spinal cord injury thus raising the possibility of ischemia (Despard 1909; Leech and Cuthbert 1972). The paraplegia at the thoracic eight level in Reichert and Martin case could be postulated as due to ischemia of the spinal cord produced by the sudden severe compression of the lower chest with secondary venous obstruction and secondary local anoxia of the spinal cord from the back pressure in the intervertebral venous plexus at the thoracic eight level (Despard 1909). Senoglu et al. presented a 4-year-old child with TA associated with intramedullary spinal cord hemorrhage following thoracic compression. They stressed the importance of spinal cord hemorrhage that can accompany TA without radiological abnormality and advised for immediate steroid therapy (Conwell 1927).

### **Peripheral nerves**

Leech and Cuthbert reported 15 cases of TA with 6 concomitant brachial plexus injuries following the major disaster of Ibrox Football Stadium at January 2, 1971. The high incidence of brachial plexus lesions in this tragedy emphasizes the diagnostic difficulty presented by a patient who is deeply unconscious with TA and with a monoparesis; such a patient may be considered to be suffering from a serious head injury with a lateralizing sign warranting urgent neurosurgical investigation (Leech and Cuthbert 1972).

### **Vision**

Post-traumatic retinal changes with visual loss were noted in 1911 by Purtscher (Purtscher's retinopathy) (Macnab et al. 1987; Sertaridou et al. 2012). The prognosis for vision after TA is usually good, and vision loss is usually temporary if there is no retinal angiopathy. But there have been a few cases of immediate or late blindness caused by retinal hemorrhages and cotton wool exudates in the fundus, which is known as traumatic retinal angiopathy (Choi et al. 2010). Decreased vision, blurred vision, papillary changes, optic nerve atrophy, diplopia, and exophthalmia are the most frequent ocular findings (Gulbahar et al. 2015). The high retrograde venous pressure in the head and neck may be associated with

neuronal ischemia, which can lead to irreversible optic nerve atrophy. It is therefore important to carry out an early, routine, and complete ophthalmologic examination, especially in the intubated and poorly cooperative patients (Tibor et al. 2017).

### **Ear and nose**

A hearing deficit can be caused by edema of the Eustachian tubes, or a hemotympanum (Sertaridou et al. 2012; Gulbahar et al. 2015). Westphal et al. from Brazil reported a case of TA with perforation of tympanic membrane (Westphal et al. 2013). Epistaxis may occur due to capillary rupture (Gulbahar et al. 2015).

### **Traumatic asphyxia in children**

Fatal TA in childhood is a rare event (Byard et al. 2003), and its pathophysiology is different compared to adults, because of the greater elasticity of the thorax in children (El Koraichi et al. 2012). Unsupervised play of young children around heavy and potentially unstable pieces of furniture may be dangerous (Byard et al. 2003; Byard 2015; Cortis et al. 2015). Montes-Tapia et al. reported 3 pediatric cases 18, 20, and 36 months of age who presented with signs and symptoms of TA after car accidents (Montes-Tapia et al. 2014). Accidental death from chest compression may also occur when an adult roll onto an infant while sleeping. A 6-year-old boy suffered TA when his T-shirt was caught in a rotating shaft at the back of a tractor and compressed his chest (Eken and Yigit 2009). Cortis et al. reported a 19-month-old boy whose right arm was caught between the elements of an automatic revolving door. As a direct result of rescue attempts, the child's body was drawn further into the narrow gap between elements of the door. The child died because of head injury and thoracic compression (Cortis et al. 2015). A very rare case of asphyxia by thorax compression was also reported where an infant died when a python tightened around it (Miyaiishi et al. 2004).

### **Management of traumatic asphyxia**

The diagnosis of TA should be easily made with inspection of the patient following a careful history. The diagnostic work up aims to outline the extent of associated injuries and determine their severity. Plain radiographs, imaging studies, ECG, echocardiography, and brain CT scan may be needed. Some authors recommend bronchoscopy in any case of TA for both diagnostic and therapeutic purposes (Lateef 2015). Supportive treatment such as oxygenation and elevation of the head to 30° is usually sufficient in the management of these patients. However, specific treatments may be needed for the associated injuries (Eken and Yigit 2009).



## Prognosis

Despite the startling findings on the face, neck, and chest, the majority of patients with TA have a favorable outcome (Shiber et al. 2013; Gulbahar et al. 2015; Lateef 2015). The prognosis of TA depends on the duration of chest compression and early cardiopulmonary resuscitation in the event of cardiopulmonary arrest (Hirade et al. 2015). Traumatic asphyxia heals spontaneously within weeks except the neurological and ocular signs (Gulbahar et al. 2015).

## Death and autopsy findings

Apnea and hypoxemia associated with prolonged thoracic compression may be life threatening and give rise to increased mortality (hypoxic encephalopathy) (Gulbahar et al. 2015; Lateef 2015; Motomura et al. 2019). When death occurs, it is usually due to a combination of asphyxia, resulting from compression of the torso and thorax, and pulmonary congestion. A further factor is a pulmonary micro-embolism syndrome resulting from the influx of fat (Cortis et al. 2015). At the autopsy, subpleural petechiae (58.5%) and petrous ridge hemorrhage (without skull base fracture) (56.6%) were the most common findings in one study. According to the authors, in cases without hospitalization, any of the following signs may lead the physician to a postmortem diagnosis of TA: petechiae on the upper parts of the body and conjunctiva, petechiae on serous membranes (including subpleural regions), and signs of petrous ridge hemorrhage without skull base fracture (Arslan et al. 2018).

## Conclusions

Despite its rarity, physicians who are clinically aware of traumatic asphyxia should face no difficulty in making the correct diagnosis of traumatic asphyxia. Traumatic asphyxia should be thought of in all cases of blunt trauma to the chest and/or upper abdomen which present with edema and blue discoloration of the face and neck beside sub-conjunctival hemorrhage. Due to its widespread lesions, traumatic asphyxia should be looked upon as a systemic syndrome. Timely accurate diagnosis and supportive treatment save the majority of patients with traumatic asphyxia.

## Abbreviations

BP: Blood pressure; CT: Computerized scan; CXR: Chest X-ray; ECG: Electrocardiography; IV: Intravenous; IVC: Inferior vena cava; SOB: Shortness of breath; SVC: Superior vena cava; TA: Traumatic asphyxia; t.d.s: Three times a day.

## Acknowledgements

None to be mentioned.

## Author's contributions

AYT had provided the clinical management, created research idea and design, collected the data, reviewed the relevant literature, and wrote the main text. The author has read and approved the manuscript.

## Funding

The author declares that he has received no funding for conducting this study.

## Availability of data and materials

All data generated or analyzed during this study are included in this published article. No statistical analysis was performed as it was not applicable.

## Declarations

### Ethics approval and consent to participate

This study was approved by the Ethical Committee of University of Sulaimani College of Medicine (Number 33), and informed written consent was obtained from the participants.

### Consent for publication

Informed consents were taken from the patients for publication purposes. Written informed consent to publish the images with the facial region was obtained from study participant's next of kin and/or parent/legal guardian. Proof of consent to publish from study participants can be supplied at any time. The images provided showed the faces of the patients due to the presence of significant physical findings of traumatic asphyxia in the region of the face which are essential in the presentation, but we have already obtained the agreement of the patients to show their faces.

### Competing interests

The author declares that he has no competing interests.

Received: 9 December 2021 Accepted: 23 May 2022

Published online: 30 May 2022

## References

- Arslan MN et al (2018) Comparison of autopsy findings and injury severity scores in deaths due to traumatic asphyxia (perthes syndrome). *J Forensic Leg Med* 56:42–47. <https://doi.org/10.1016/j.jflm.2018.03.002>
- Byard RW (2015) Traumatic asphyxia in the young. *Int J Leg Med* 129(5):1109. <https://doi.org/10.1007/s00414-015-1220-4>
- Byard RW, Hanson KA, James RA (2003) Fatal unintentional traumatic asphyxia in childhood. *J Paediatr Child Health* 39(1):31–32. <https://doi.org/10.1046/j.1440-1754.2003.00067.x>
- Byard RW et al (2006) The pathological features and circumstances of death of lethal crush/traumatic asphyxia in adults—A 25-year study. *Forensic Sci Int* 159(2–3):200–205. <https://doi.org/10.1016/j.forsciint.2005.08.003>
- Cappelletti S et al (2019) A lethal case of hoarding due to the combination of traumatic and confined space asphyxia. *Forensic Sci Med Pathol* 15:114–118
- Choi YJ et al (2010) Bilateral retrobulbar hemorrhage and visual loss following traumatic asphyxia. *Korean J Ophthalmol* 24(6):380–383. <https://doi.org/10.3341/kjo.2010.24.6.380>
- Conwell H (1927) Traumatic asphyxia: report of four cases. *Jbjs* 9(1):106
- Cortis J, Falk J, Rothschild MA (2015) Traumatic asphyxia—fatal accident in an automatic revolving door. *Int J Leg Med* 129(5):1103–1108. <https://doi.org/10.1007/s00414-015-1169-3>
- Despard DL (1909) Traumatic asphyxia: with report of a case. *Ann Surg* 49(6):751–761
- Domènech MS et al (2012) The murderer is the bed: an unusual case of death by traumatic asphyxia in a hotel folding bunk bed. *Forensic Sci Int* 220(1–3):2–3. <https://doi.org/10.1016/j.forsciint.2012.01.031>
- Eken C, Yigit O (2009) Traumatic asphyxia: a rare syndrome in trauma patients. *Int J Emerg Med* 2(4):255–256. <https://doi.org/10.1007/s12245-009-0115-x>
- El Koraichi A et al (2012) Syndrome d'asphyxie traumatique ou syndrome de Perthes : À propos de deux observations pédiatriques [Traumatic asphyxia or Perthes Syndrome. About two paediatric cases]. *Annal*

- Francaises d'Anesthesie et de Reanimation 31(3):259–261. <https://doi.org/10.1016/j.jannfar.2011.12.011>
- Gulbahar G et al (2015) A rare and serious syndrome that requires attention in emergency service: traumatic asphyxia. *Case Rep Emerg Med* 2015:1–4. <https://doi.org/10.1155/2015/359814>
- Heuer G (1923) Traumatic asphyxia: with especial reference to its ocular and visual disturbances. *Surg Gynecol Obstet* 36:686–696. <https://doi.org/10.3918/jsicm.19.75>
- Hirade T et al (2015) Full recovery from cardiopulmonary arrest caused by traumatic asphyxia. *Kyobu Geka* 68(3):171–175
- Kamali S et al (2013) A case of traumatic asphyxia due to motorcycle accident. *Case Rep Emerg Med* 2013:1–3. <https://doi.org/10.1155/2013/857131>
- Karamustafaoglu YA et al (2010) Traumatic asphyxia. *Int J Emerg Med* 3(4):379–380. <https://doi.org/10.1007/s12245-010-0204-x>
- Landercasper J, Cogbill T (1985) Long term follow up after traumatic asphyxia. *J Trauma* 25:838–841
- Lateef H (2015) Traumatic asphyxia with diaphragmatic injury: a case report. *Oman Med J* 30(2):142–145. <https://doi.org/10.5001/omj.2015.30>
- Lee MC et al (1991) Traumatic asphyxia. *Ann Thorac Surg* 51(1):86–88. [https://doi.org/10.1016/0003-4975\(91\)90456-Z](https://doi.org/10.1016/0003-4975(91)90456-Z)
- Leech P, Cuthbert H (1972) Brachial plexus lesions associated with traumatic asphyxia. *Br J Surg* 59(7):539–541. <https://doi.org/10.1002/bjs.1800590709>
- Macnab AJ et al (1987) Proptosis and diplopia following traumatic asphyxia. *Ann Emerg Med* 16(11):1289–1290. [https://doi.org/10.1016/S0196-0644\(87\)80242-1](https://doi.org/10.1016/S0196-0644(87)80242-1)
- Marcus JT et al (2019) Vena cava backflow and right ventricular stiffness in pulmonary arterial hypertension. *Eur Respir J* 54(4). <https://doi.org/10.1183/13993003.00625-2019>
- Miyaishi S et al (2004) Negligent homicide by traumatic asphyxia. *Int J Leg Med* 118(2):106–110. <https://doi.org/10.1007/s00414-003-0423-2>
- Montes-Tapia F et al (2014) Traumatic asphyxia. *Pediatr Emerg Care* 30(2):114–116. <https://doi.org/10.1097/PEC.0000000000000067>
- Motomura T et al (2019) Thoracoabdominal compression model of traumatic asphyxia to identify mechanisms of respiratory failure in fatal crowd accidents. *J Nippon Med Sch* 86(6):310–321. [https://doi.org/10.1272/jnms.JNMS.2019\\_86-607](https://doi.org/10.1272/jnms.JNMS.2019_86-607)
- Reichert FL, Martin JW (1951) Traumatic asphyxia: experimental and clinical observations with a report of a case with concomitant paraplegia. *Ann Surg* 134(3):361–368
- Sertaridou E et al (2012) Traumatic asphyxia due to blunt chest trauma: a case report and literature review. *J Med Case Reports* 6:1–5. <https://doi.org/10.1186/1752-1947-6-257>
- Shiber JR, Fontane E, Monroe B (2013) Olivier syndrome: traumatic asphyxia. *West J Emerg Med* 14(6):653. <https://doi.org/10.5811/westjem.2013.7.18581>
- Tibor K et al (2017) Traumatic asphyxia with permanent visual loss. *Orv Hetil* 158(22):864–868. <https://doi.org/10.1556/650.2017.30750>
- Tucker WD, Shrestha R, Burns B (2021) Anatomy, abdomen and pelvis, inferior vena cava. In: StatPearls (ed) StatPearls Publishing, Treasure Island, Available at: <http://www.ncbi.nlm.nih.gov/pubmed/29493975>
- Westphal FL et al (2013) Tympanic membrane perforation caused by traumatic asphyxia. *Braz J Otorhinolaryngol* 79(1):122. <https://doi.org/10.5935/1808-8694.20130023>

## Publisher's Note

Springer Nature remains neutral with regard to jurisdictional claims in published maps and institutional affiliations.

Submit your manuscript to a SpringerOpen<sup>®</sup> journal and benefit from:

- Convenient online submission
- Rigorous peer review
- Open access: articles freely available online
- High visibility within the field
- Retaining the copyright to your article

---

Submit your next manuscript at ► [springeropen.com](https://www.springeropen.com)

---